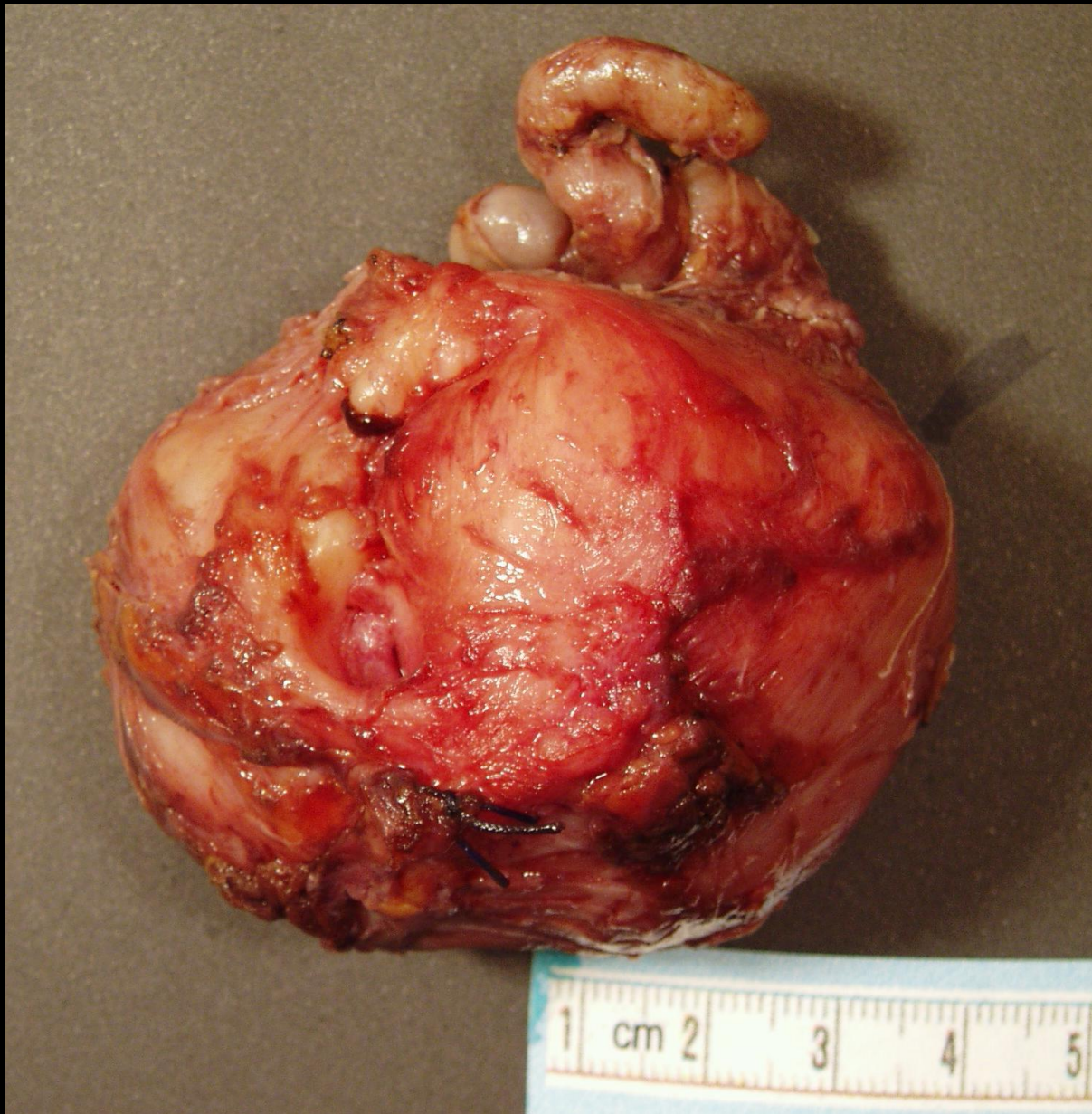

Radikal Prostatektomide Patolojik Deęerlendirme

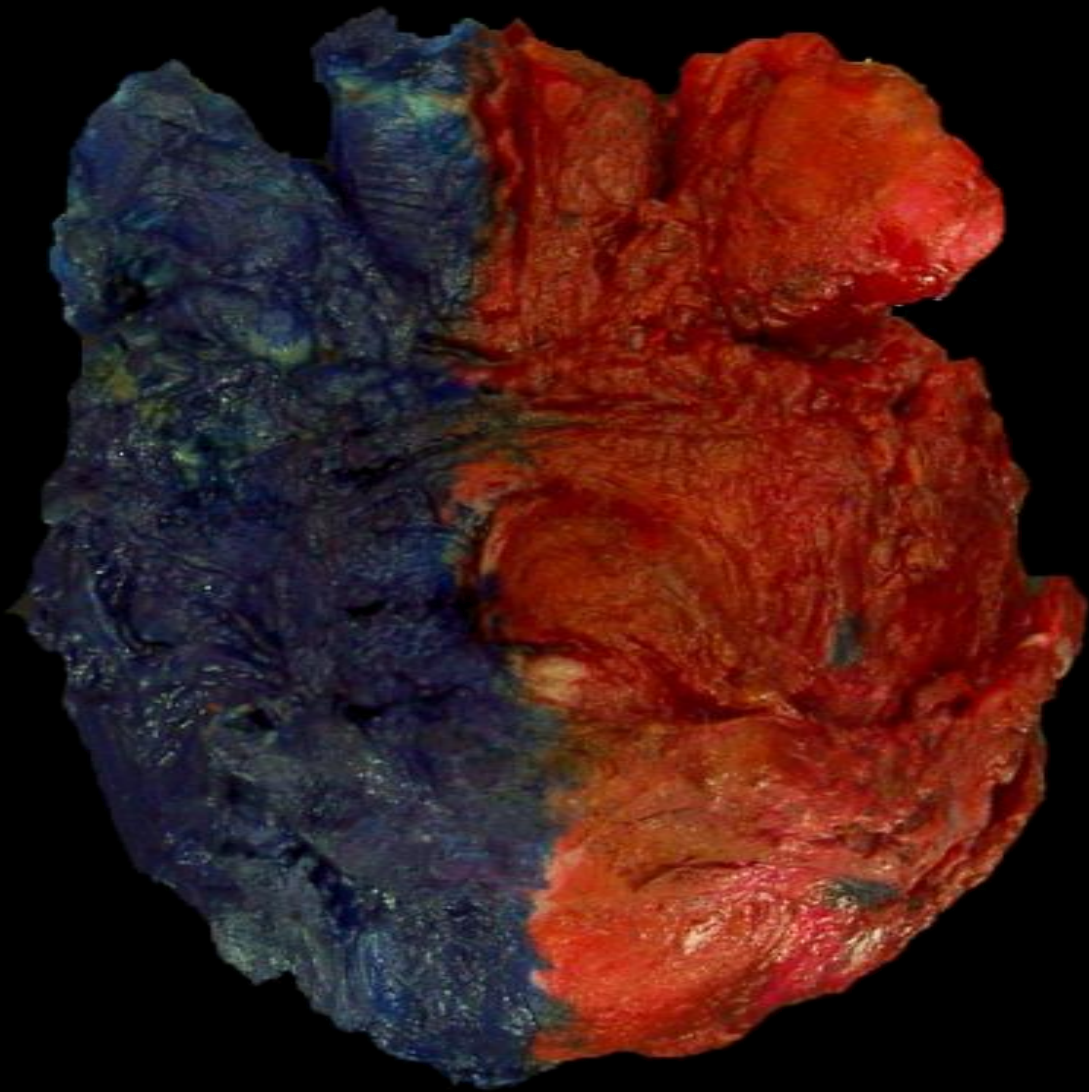
Kutsal Yörükoęlu
Dokuz Eylül Üniversitesi Tıp Fakültesi
Patoloji Anabilim Dalı

21. Ulusal Patoloji Kongresi
Ürogenital Patoloji Kursu
16 Kasım 2011, İzmir









TESPİT

- Formalin, 24 saat
- 10 cc şiringa, 22g uç, 20 cc formalin
- 300 cc formalin, 6 dk, 50°C, MW
 - >50g, +10 dk



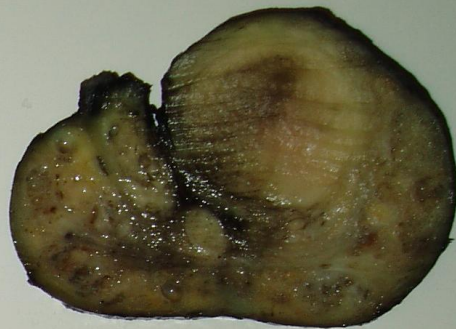
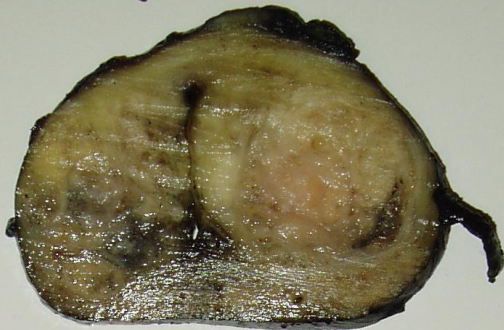




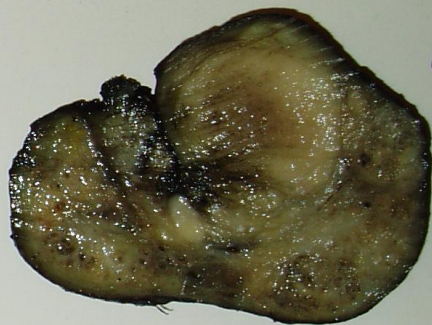
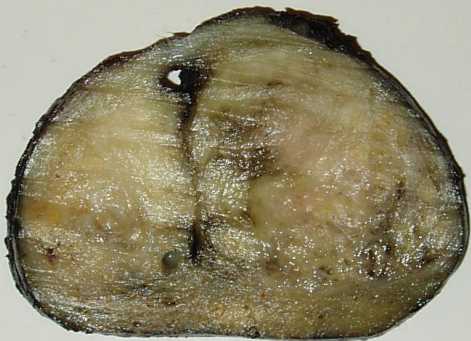
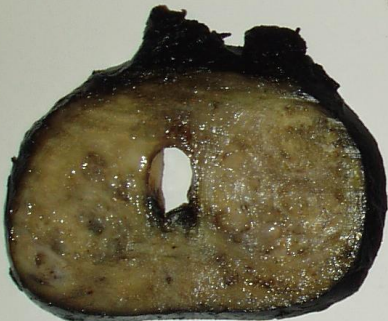



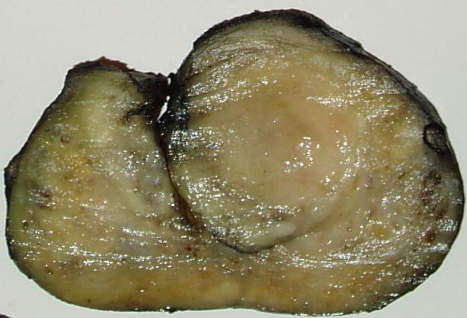
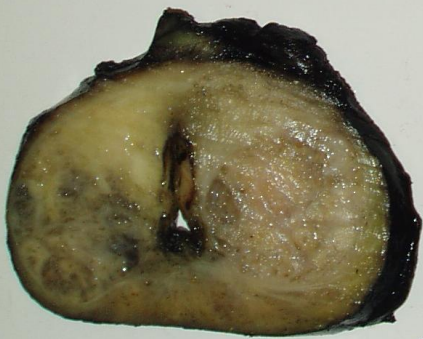
A



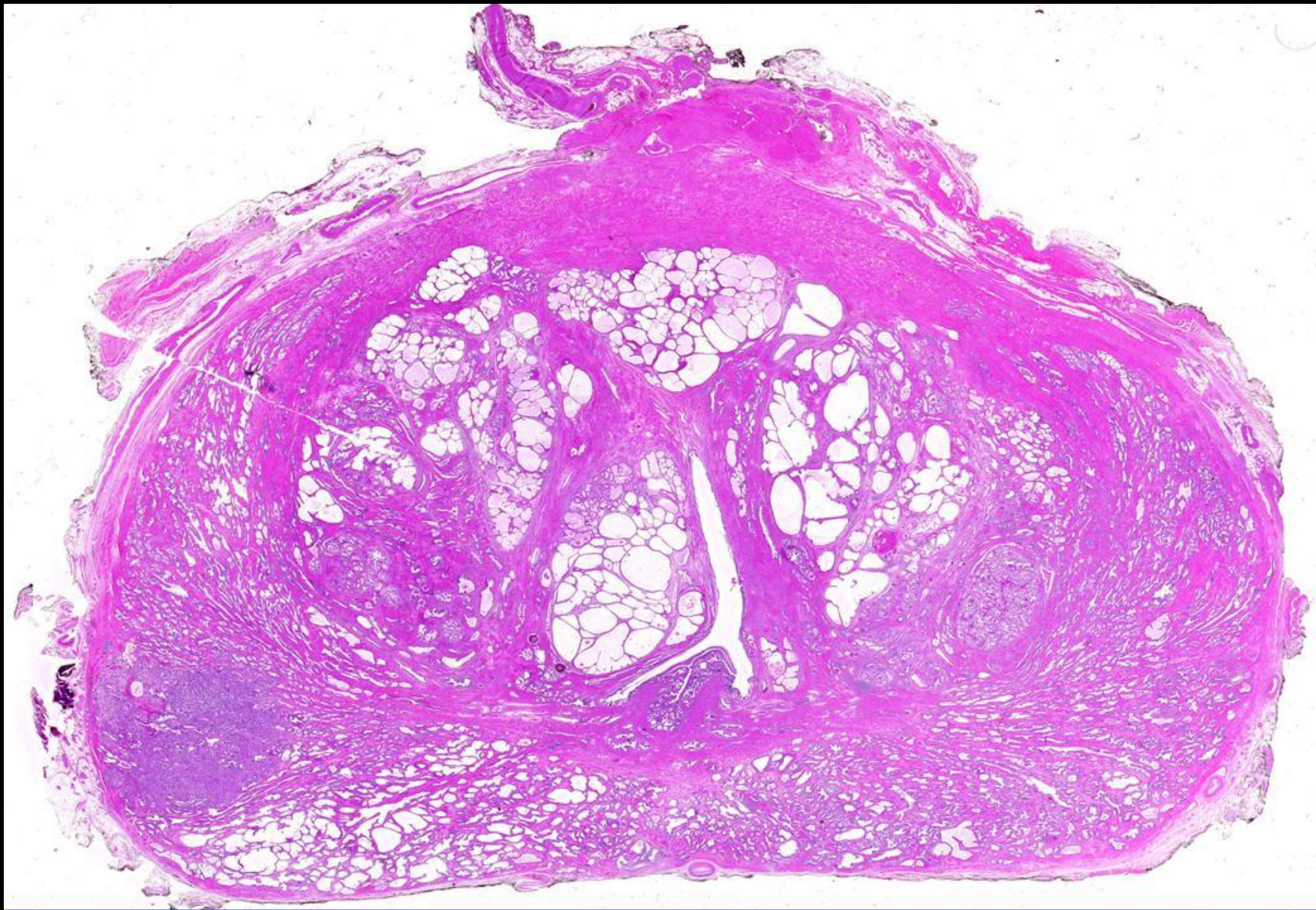
R



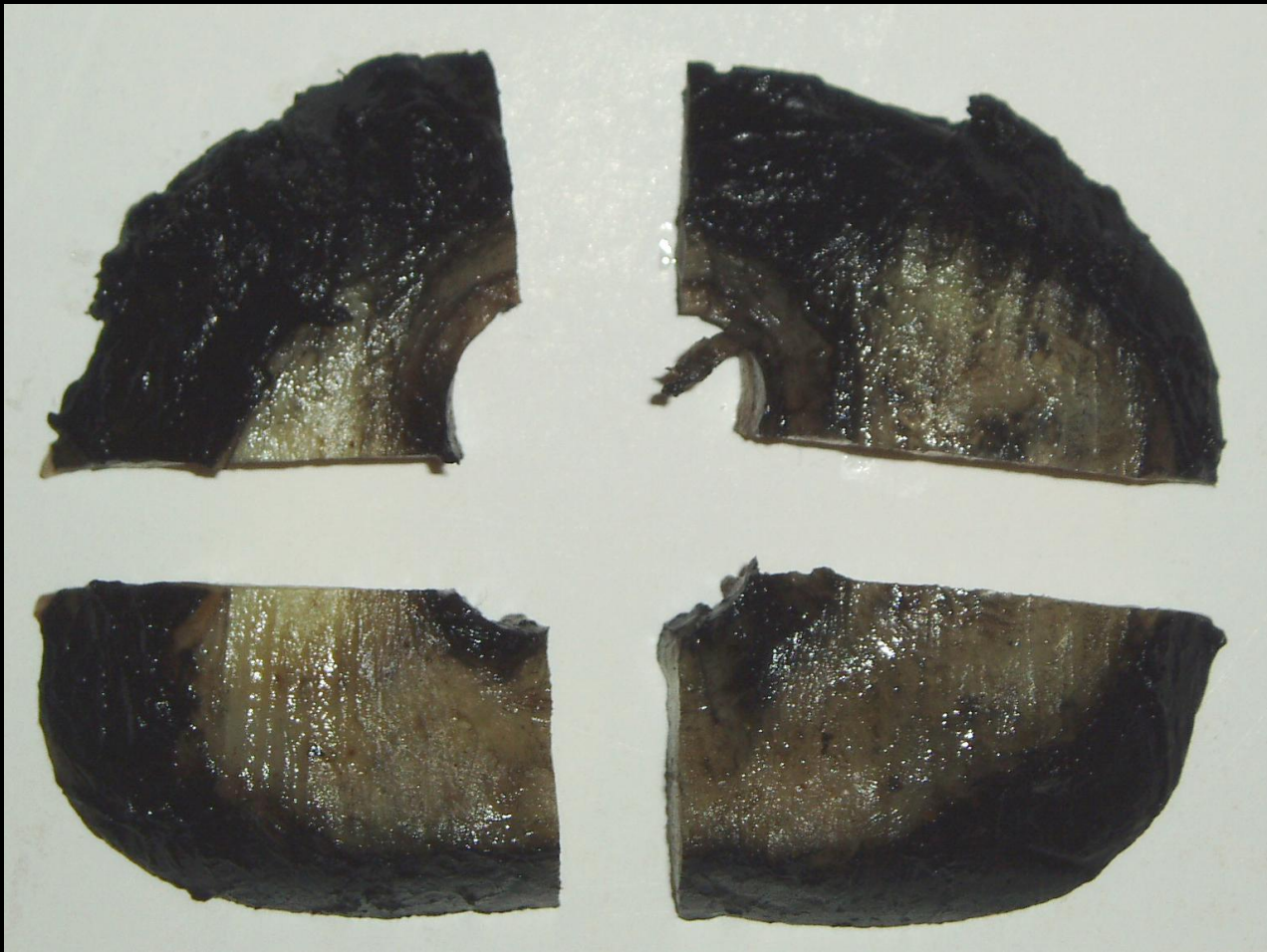
L



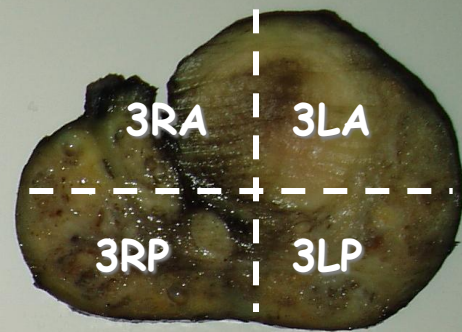
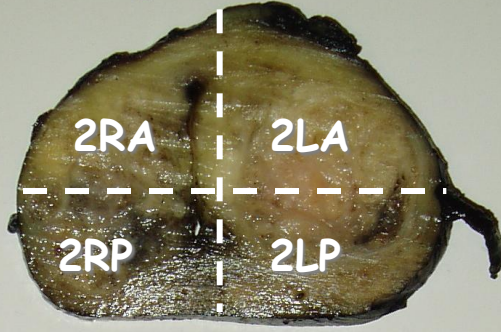
P



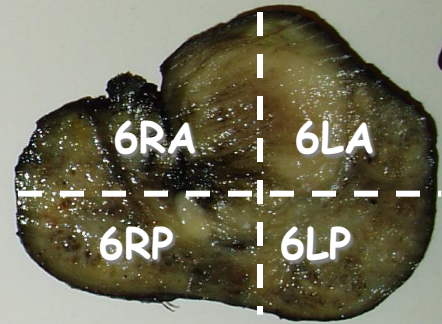
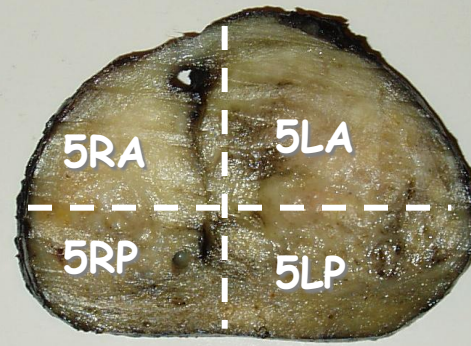

TOTAL



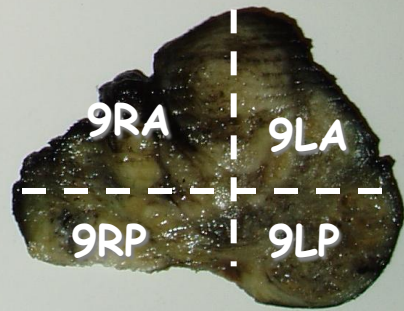
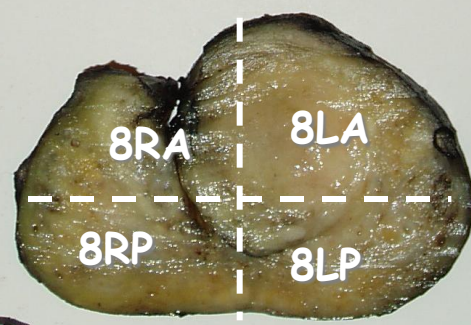
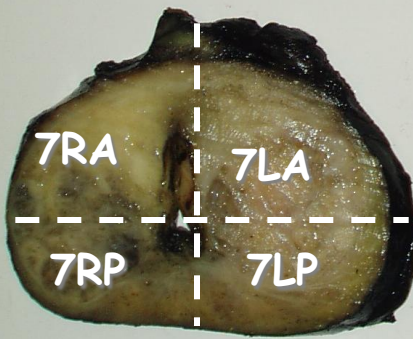
A



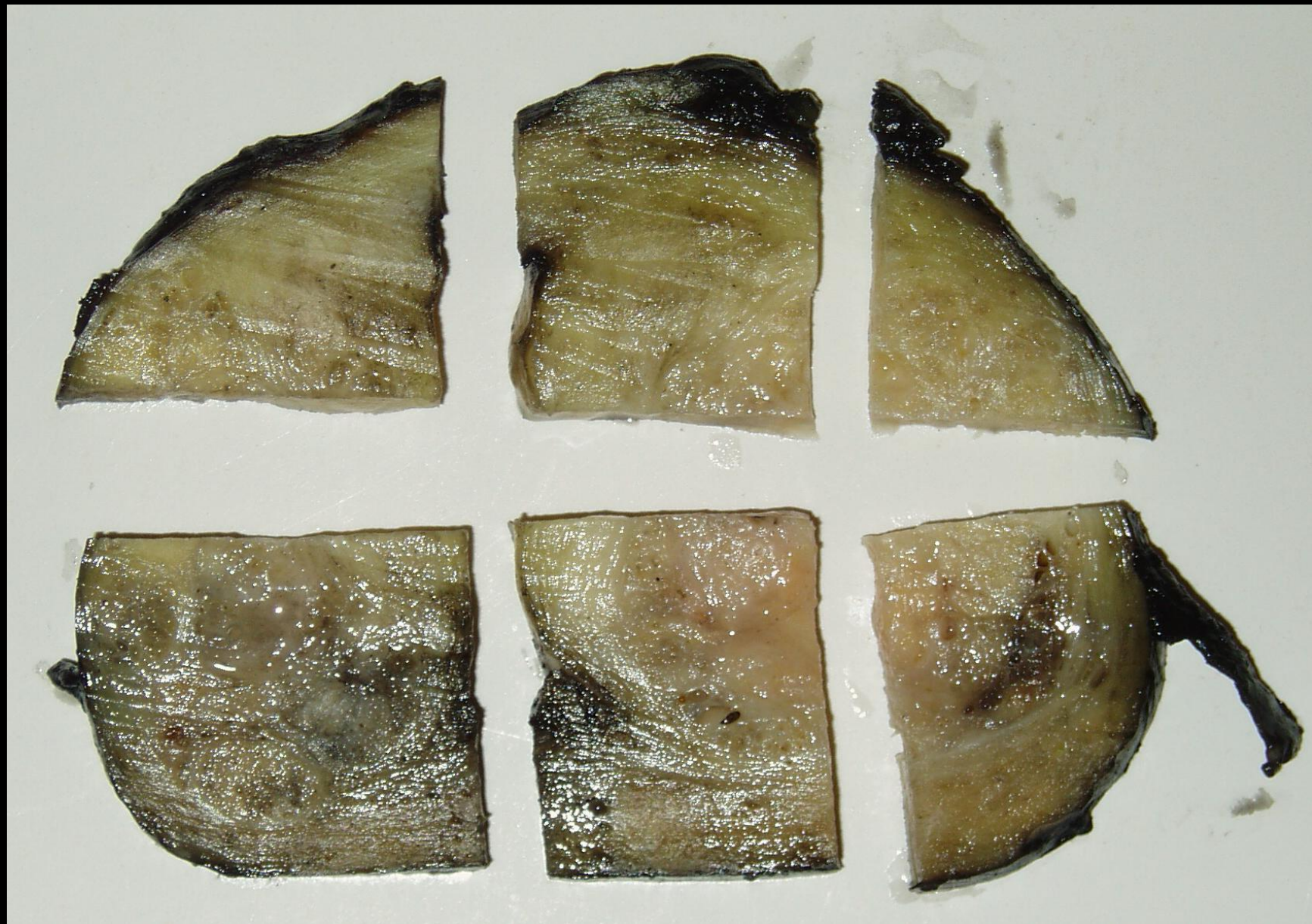R



L



P



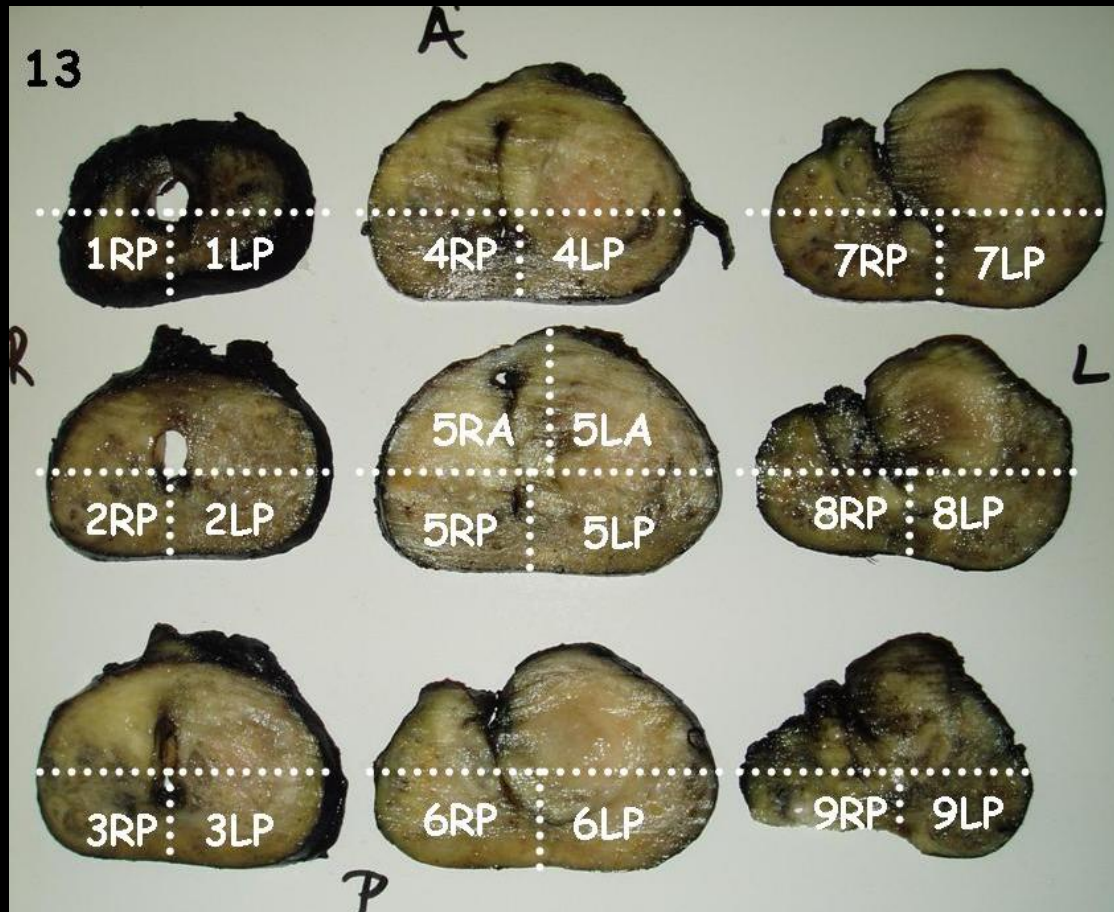
1. RA1: 1 parça 1 kasette işleme alındı.
2. LA1: 1 parça 1 kasette işleme alındı.
3. RP1: 1 parça 1 kasette işleme alındı.
4. LP1: 1 parça 1 kasette işleme alındı.
5. RA2: 1 parça 1 kasette işleme alındı.
6. LA2: 1 parça 1 kasette işleme alındı.
7. RP2: 1 parça 1 kasette işleme alındı.
8. LP2: 1 parça 1 kasette işleme alındı.
9. RA3: 1 parça 1 kasette işleme alındı.
10. LA3: 1 parça 1 kasette işleme alındı.
11. RP3: 1 parça 1 kasette işleme alındı.
12. LP3: 1 parça 1 kasette işleme alındı.
13. RA4: 1 parça 1 kasette işleme alındı.
14. LA4: 1 parça 1 kasette işleme alındı.
15. RP4: 1 parça 1 kasette işleme alındı.
16. LP4: 1 parça 1 kasette işleme alındı.
17. RA5: 1 parça 1 kasette işleme alındı.
18. LA5: 1 parça 1 kasette işleme alındı.
19. RP5: 1 parça 1 kasette işleme alındı.
20. LP5: 1 parça 1 kasette işleme alındı.
21. RA6: 1 parça 1 kasette işleme alındı.
22. LA6: 1 parça 1 kasette işleme alındı.
23. RP6: 1 parça 1 kasette işleme alındı.
24. LP6: 1 parça 1 kasette işleme alındı.
25. RA7: 1 parça 1 kasette işleme alındı.
26. LA7: 1 parça 1 kasette işleme alındı.
27. RP7: 1 parça 1 kasette işleme alındı.
28. LP7: 1 parça 1 kasette işleme alındı.
29. RA8: 1 parça 1 kasette işleme alındı.
30. LA8: 1 parça 1 kasette işleme alındı.
31. RP8: 1 parça 1 kasette işleme alındı.
32. LP8: 1 parça 1 kasette işleme alındı.
33. RA9: 1 parça 1 kasette işleme alındı.
34. LA9: 1 parça 1 kasette işleme alındı.
35. RP9: 1 parça 1 kasette işleme alındı.
36. LP9: 1 parça 1 kasette işleme alındı.
37. RA10: 1 parça 1 kasette işleme alındı.
38. LA10: 1 parça 1 kasette işleme alındı.
39. RP10: 1 parça 1 kasette işleme alındı.
40. LP10: 1 parça 1 kasette işleme alındı.
41. RA11: 1 parça 1 kasette işleme alındı.
42. LA11: 1 parça 1 kasette işleme alındı.
43. RP11: 1 parça 1 kasette işleme alındı.
44. LP11: 1 parça 1 kasette işleme alındı.
45. RA12: 1 parça 1 kasette işleme alındı.
46. LA12: 1 parça 1 kasette işleme alındı.
47. RP12: 1 parça 1 kasette işleme alındı.
48. LP12: 1 parça 1 kasette işleme alındı.
49. RA13: 1 parça 1 kasette işleme alındı.
50. LA13: 1 parça 1 kasette işleme alındı.
51. RP13: 1 parça 1 kasette işleme alındı.
52. LP13: 1 parça 1 kasette işleme alındı.
53. RA14: 1 parça 1 kasette işleme alındı.
54. LA14: 1 parça 1 kasette işleme alındı.
55. RP14: 1 parça 1 kasette işleme alındı.
56. LP14: 1 parça 1 kasette işleme alındı.
57. RA15: 1 parça 1 kasette işleme alındı.
58. LA15: 1 parça 1 kasette işleme alındı.
59. RP15: 1 parça 1 kasette işleme alındı.
60. LP15: 1 parça 1 kasette işleme alındı.
- RDCS: parça 1 kasette işleme alındı.
- LDCS: parça 1 kasette işleme alındı.
- RPCS: parça 1 kasette işleme alındı.
- LPCS: parça 1 kasette işleme alındı.
- RVS: parça 1 kasette işleme alındı.
- LVS: parça 1 kasette işleme alındı.

TÜMÜ

- Ortalama 42 blok (21-81)
- 30-60 \$ / olgu



Ürolojik Patoloji Grubu





88.4

OZT
DWT
OZ
G

COUNTING

ACCULAB V-4800

CAPACITY: 4800g READABILITY: 0.1g

ON

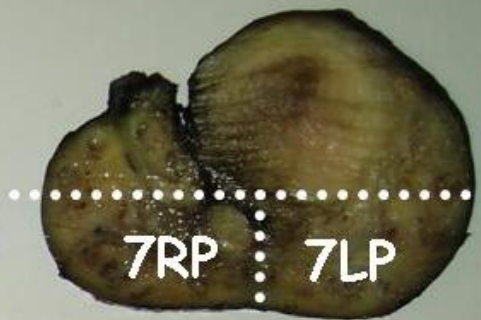
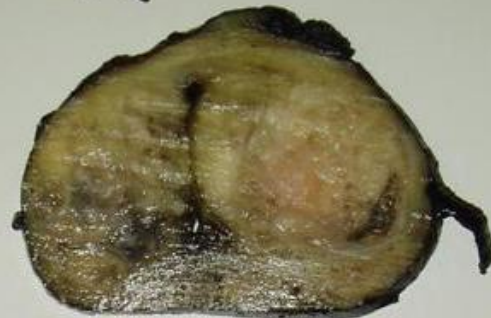
OFF

CAL
MODE

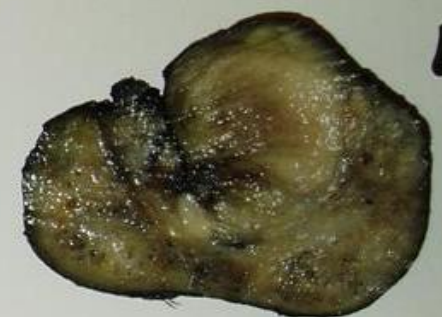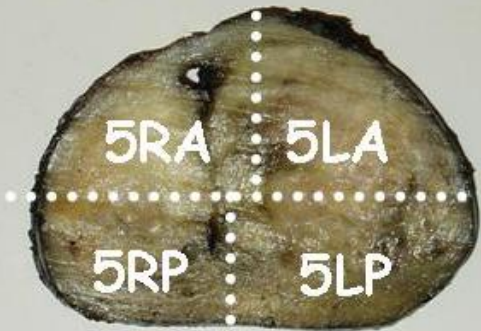
TARE

14

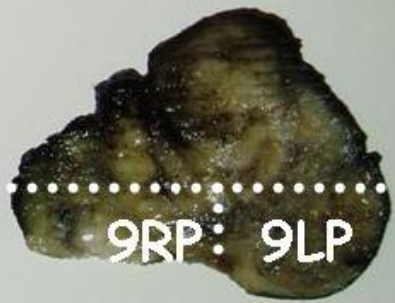
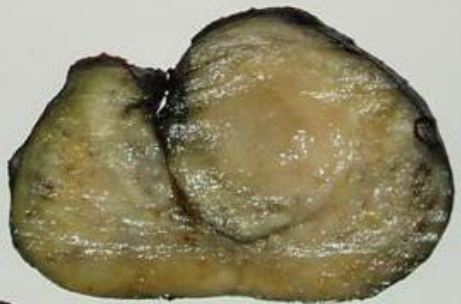
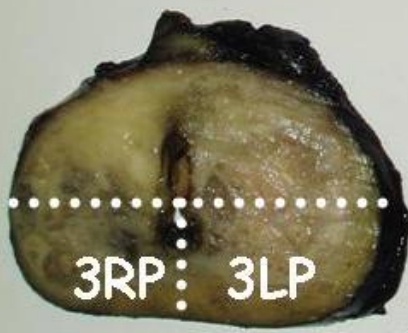
A



R

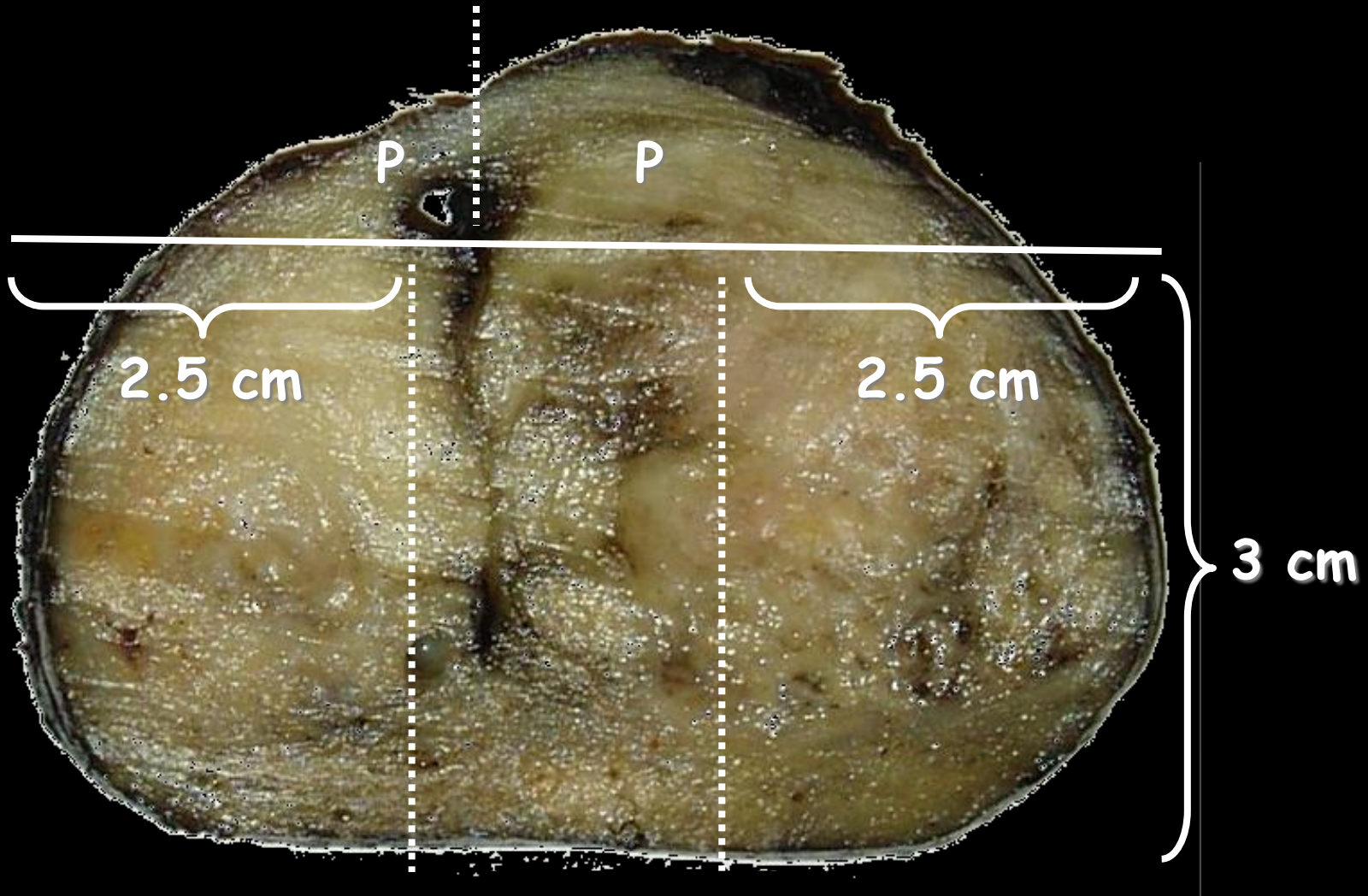


L



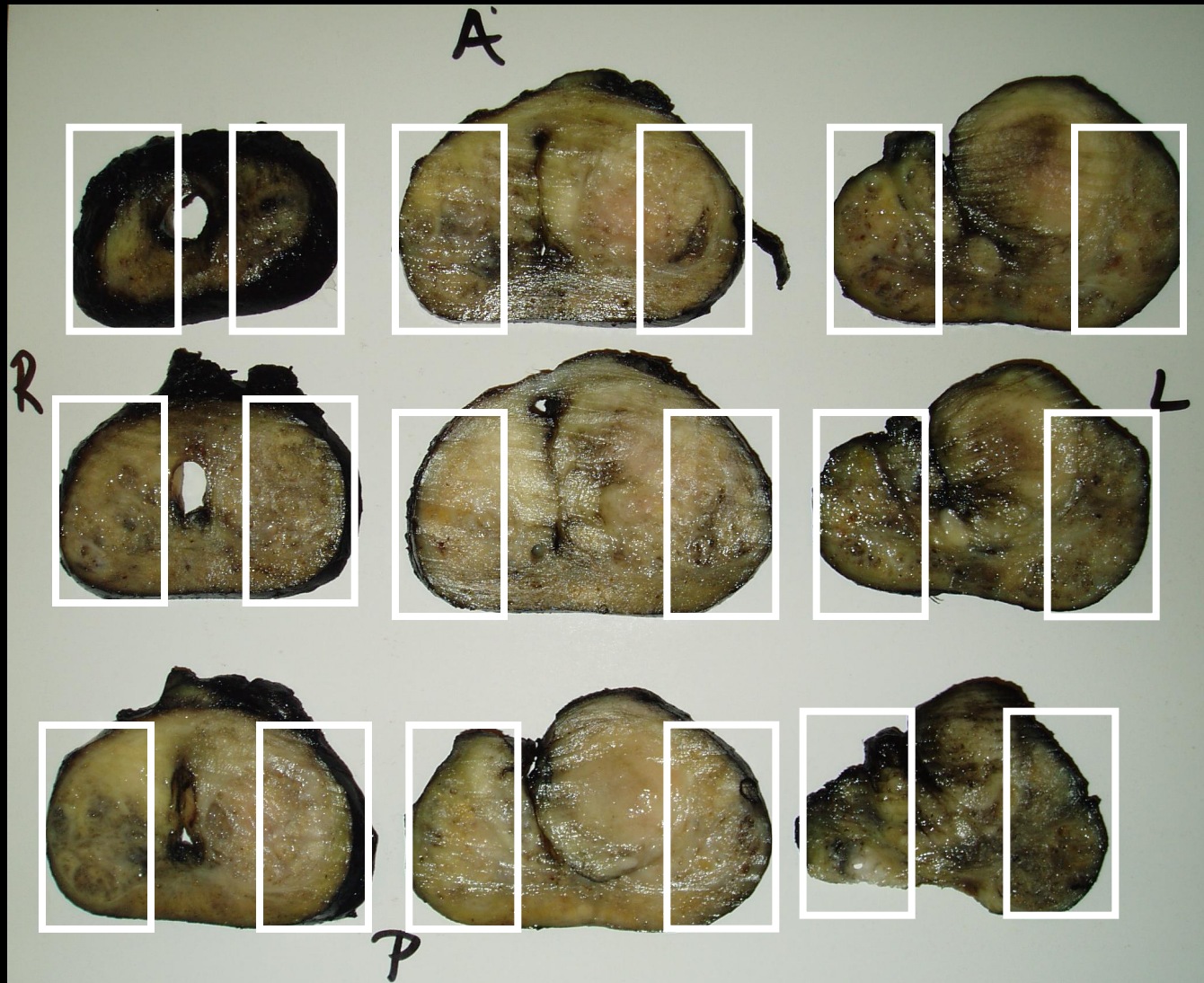
P

STANFORD



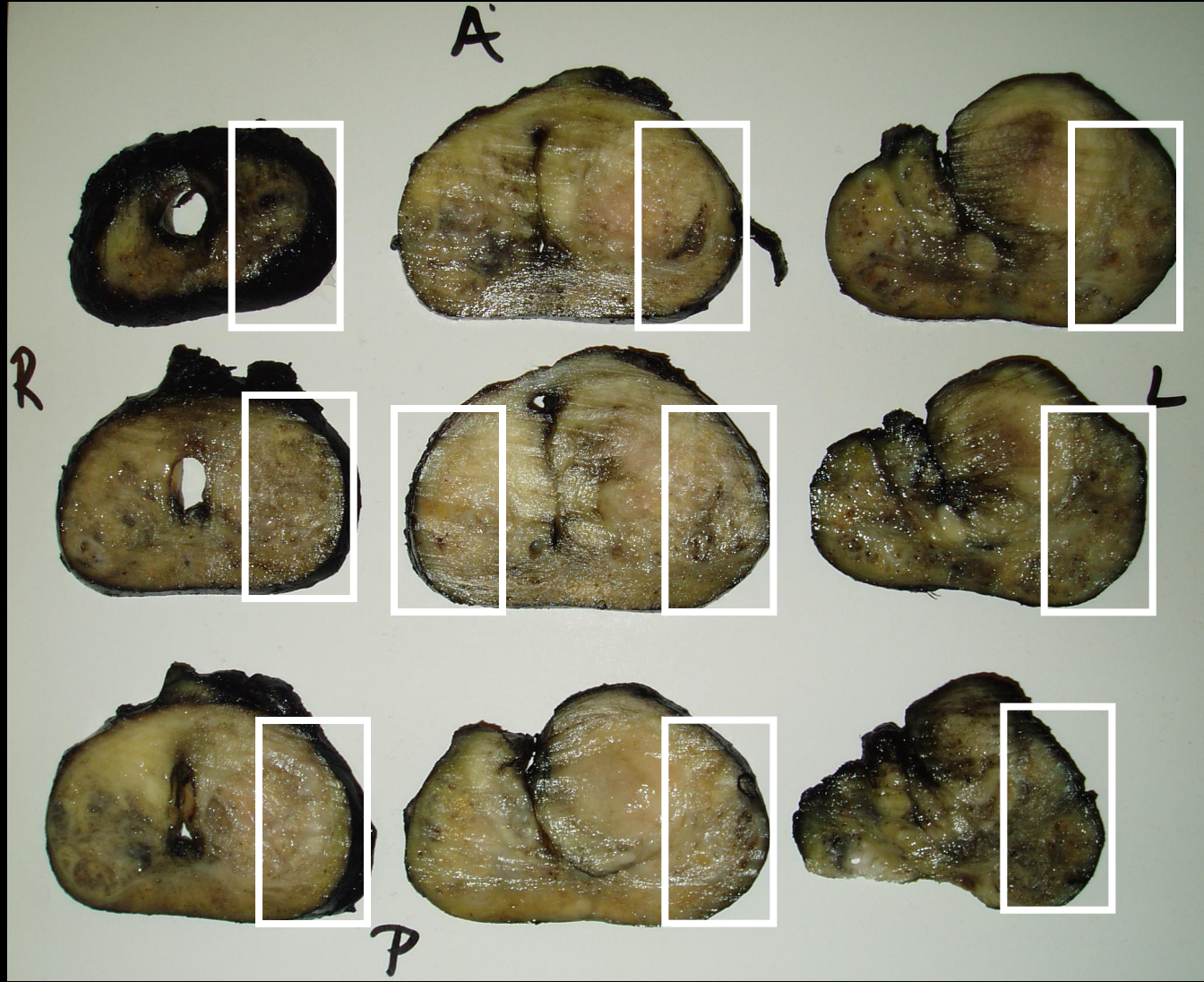
STANFORD - Bilateral

12 (8-20) blok



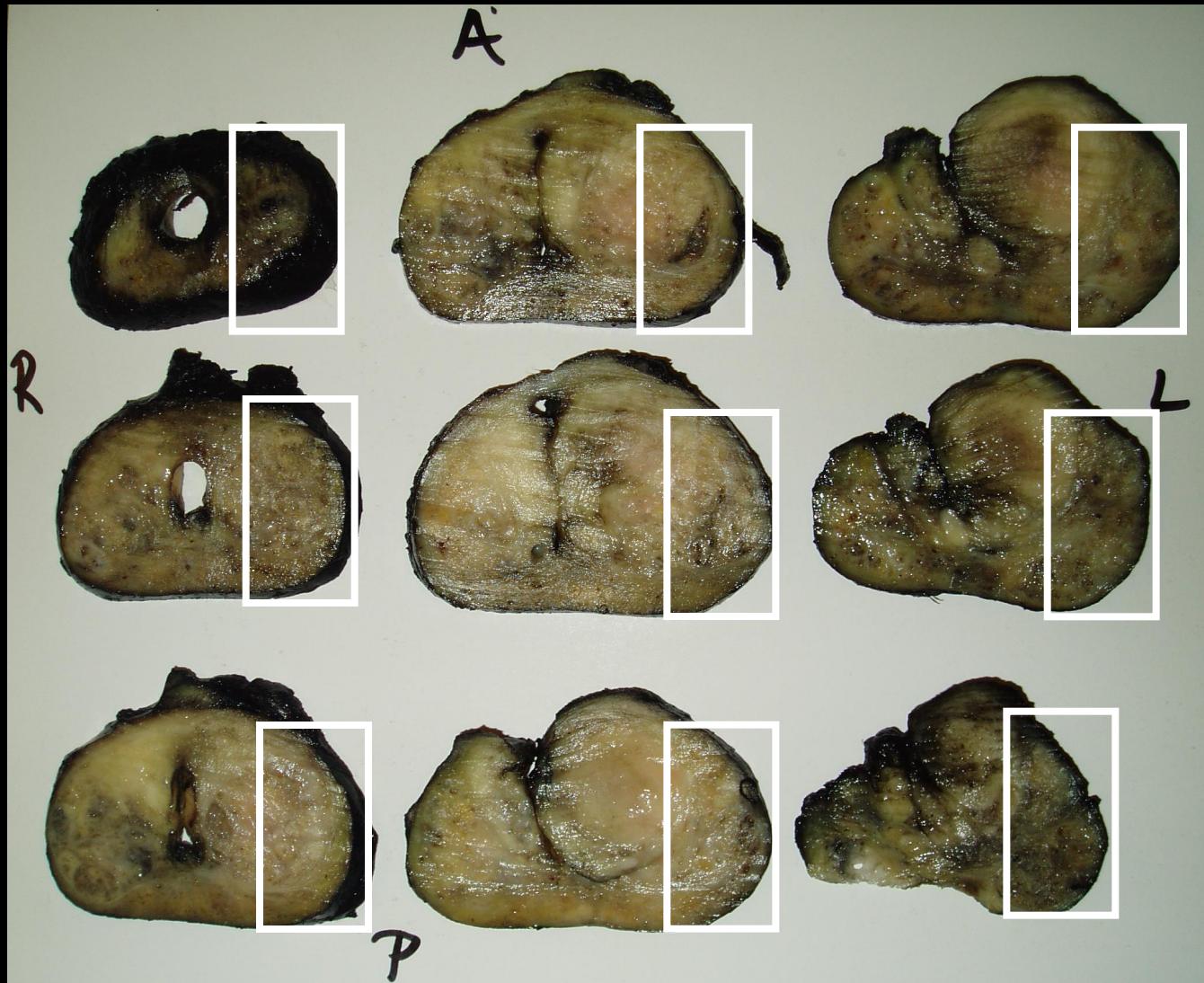
STANFORD - Parasagittal

9 (6-15) blok



STANFORD - Unilateral

6 (4-10) blok



STANFORD - Ek parça

- Anteriyorda tümör çıkarsa
 - P bloğundan atlamalı parça

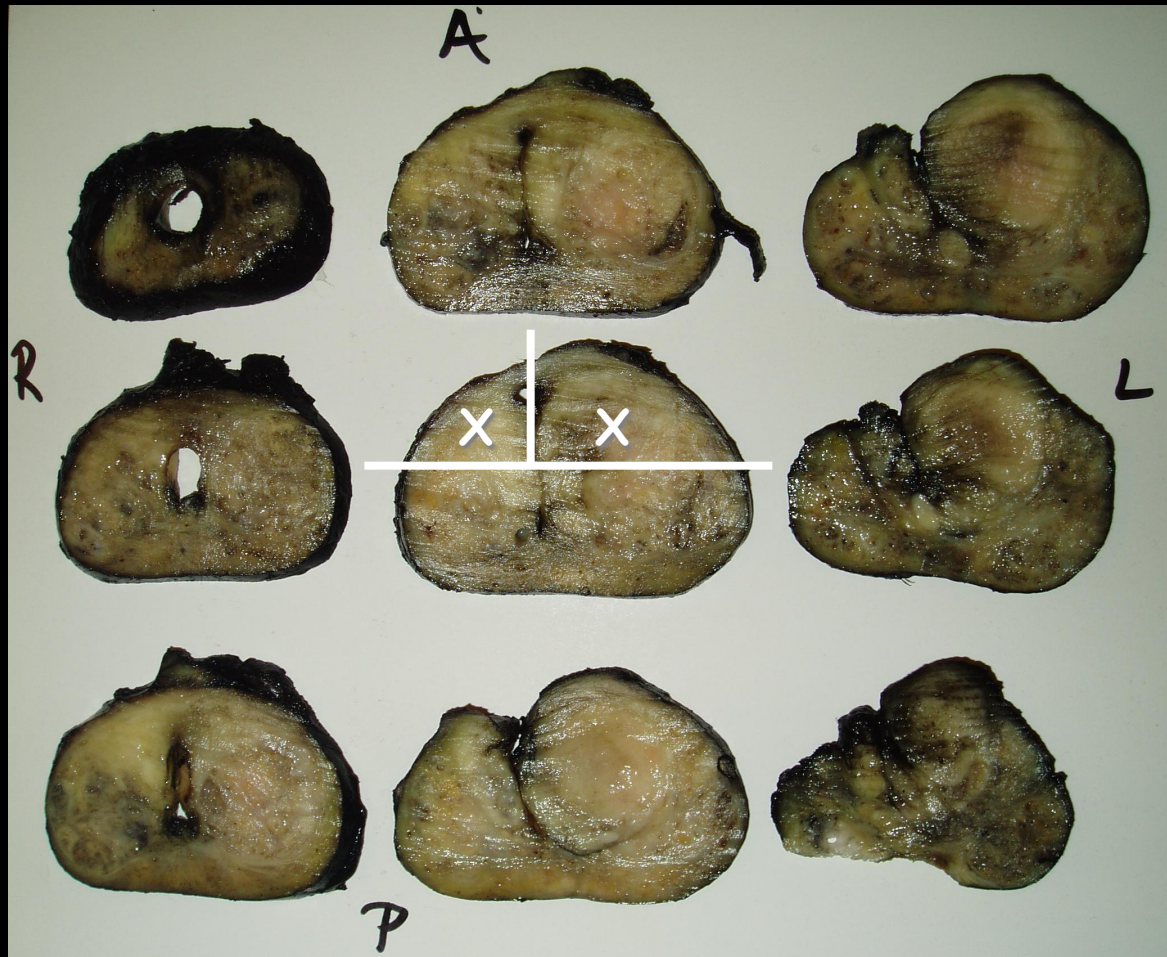
9 parsiyel + 1 total

Sehdev AES, Pan CC, Epstein JI.


Comparative analysis of sampling methods for grossing radical prostatectomy specimens performed for nonpalpable (Stage T1c) prostatic adenocarcinoma.

Hum Pathol 32:494-499, 2001.


Anterior A



1: Tüm Posterior Kesitler




2: Tüm Posterior Kesitler + Anterior A



Anterior A

- Anterior kesitlerde tümör çıkarsa ve önemli boyutta ise aynı tarafın kalan anterior parçaları işleme alınır.

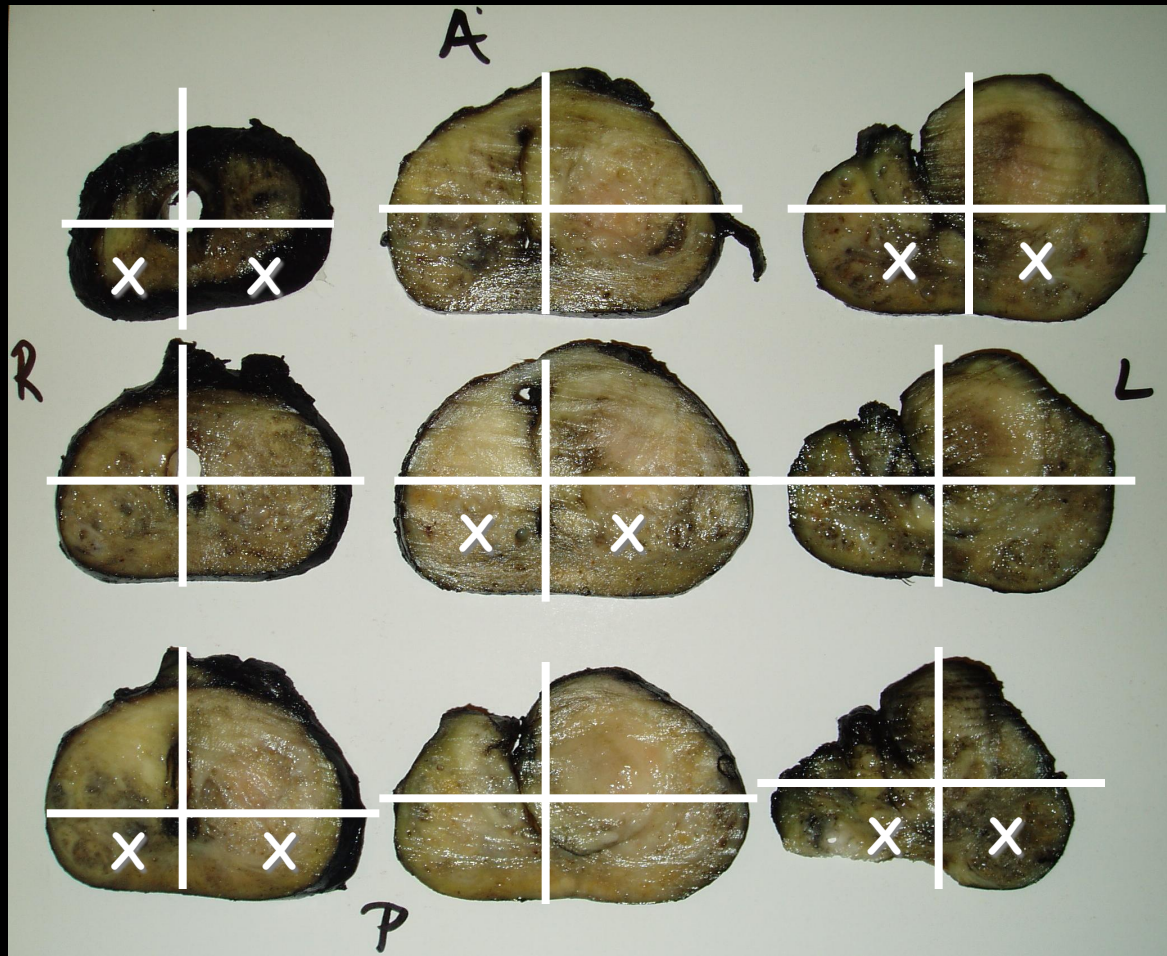
3: Tüm Posterior Kesitler + Anterior B



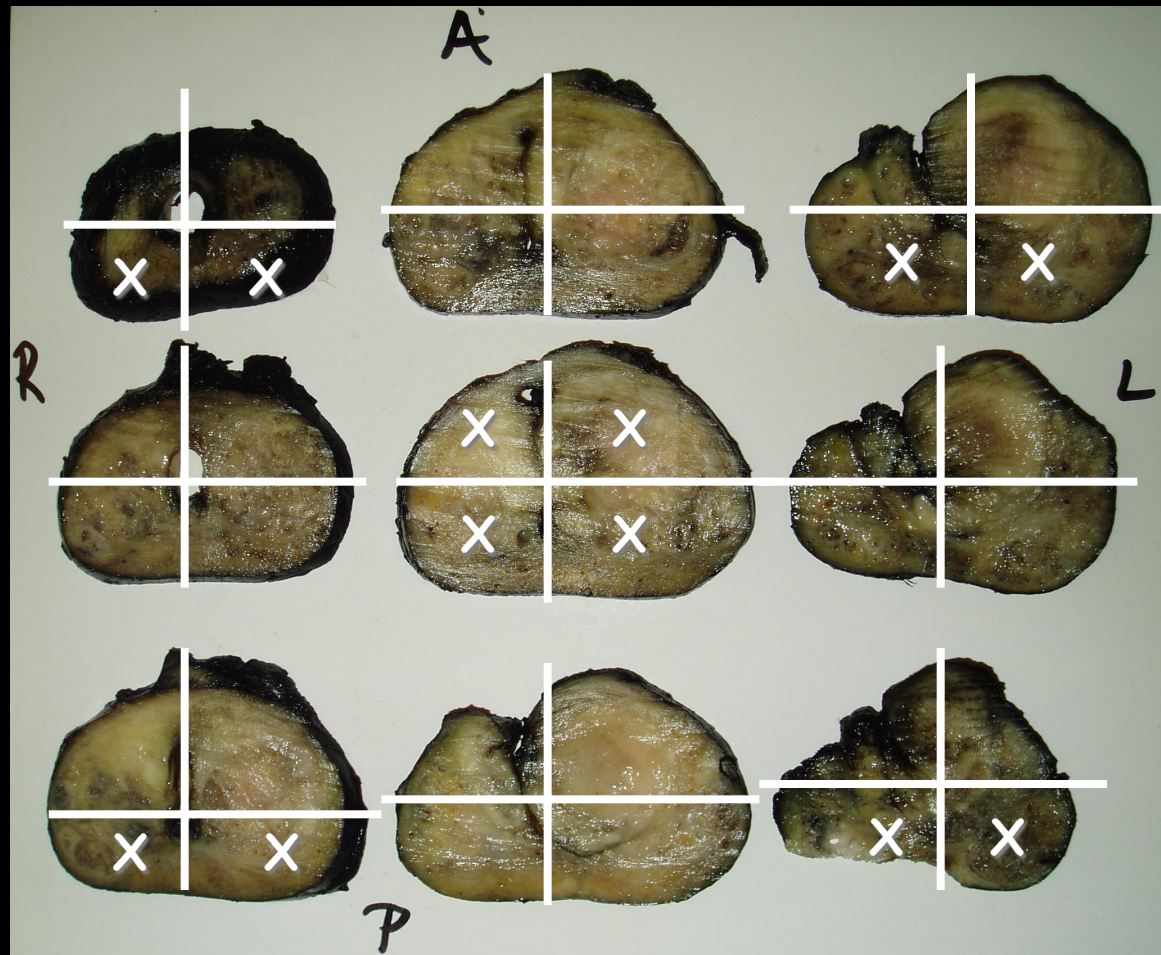
Anterior B

- Posterior kesitlerde anterior bölüme yakın ve baskın tümör çıkarsa aynı tarafın anterior parçaları işleme alınır.

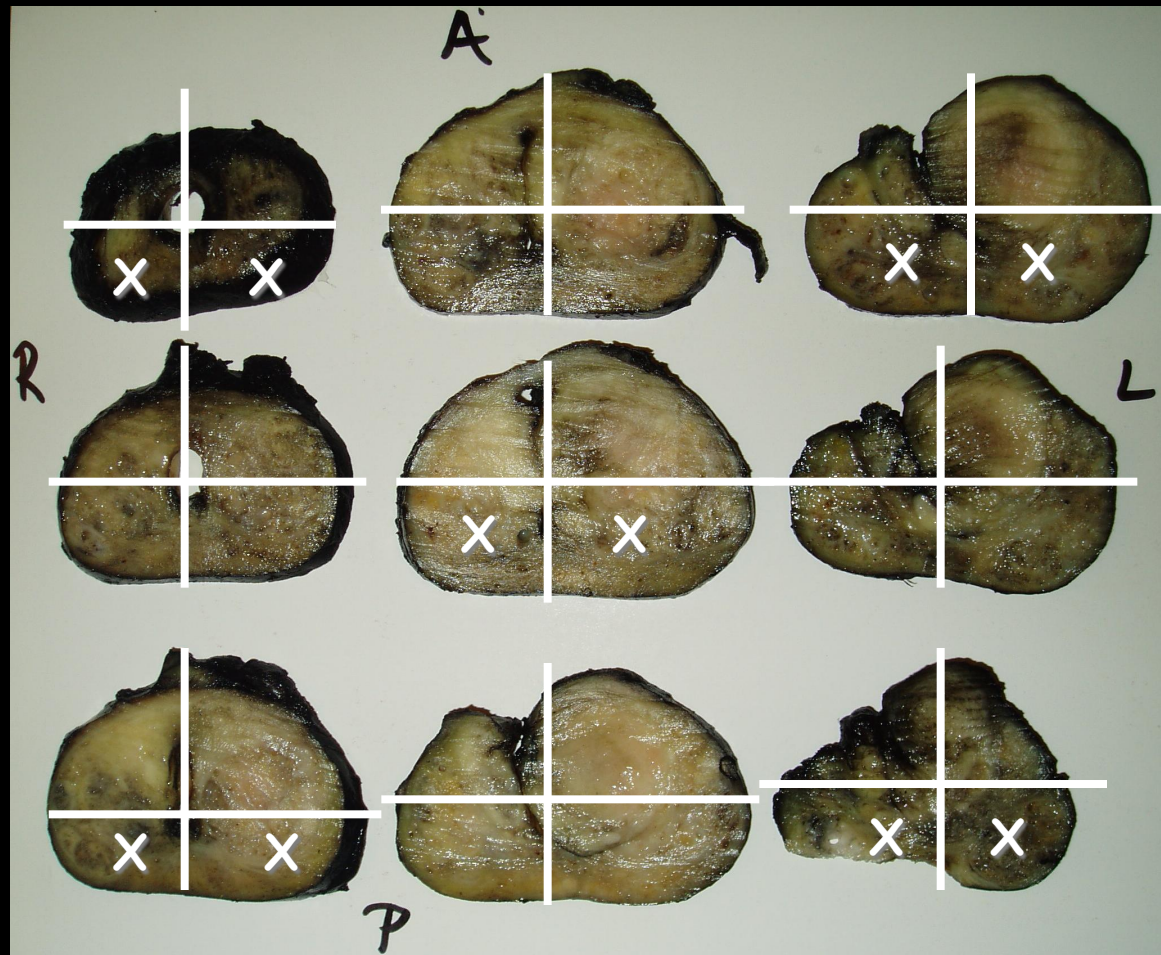
4: Atlamalı Posterior Kesitler



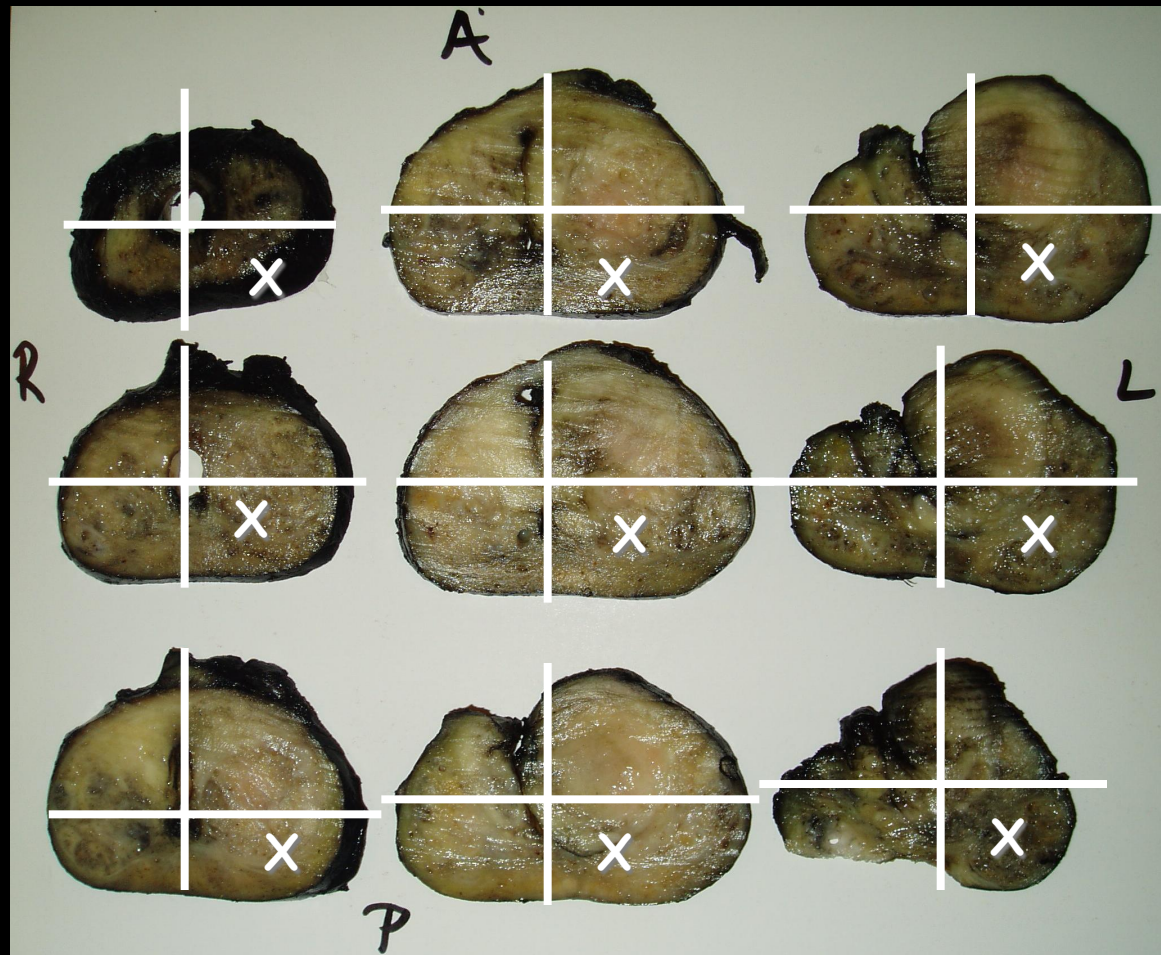
5: Atlamalı Posterior Kesitler + Anterior A



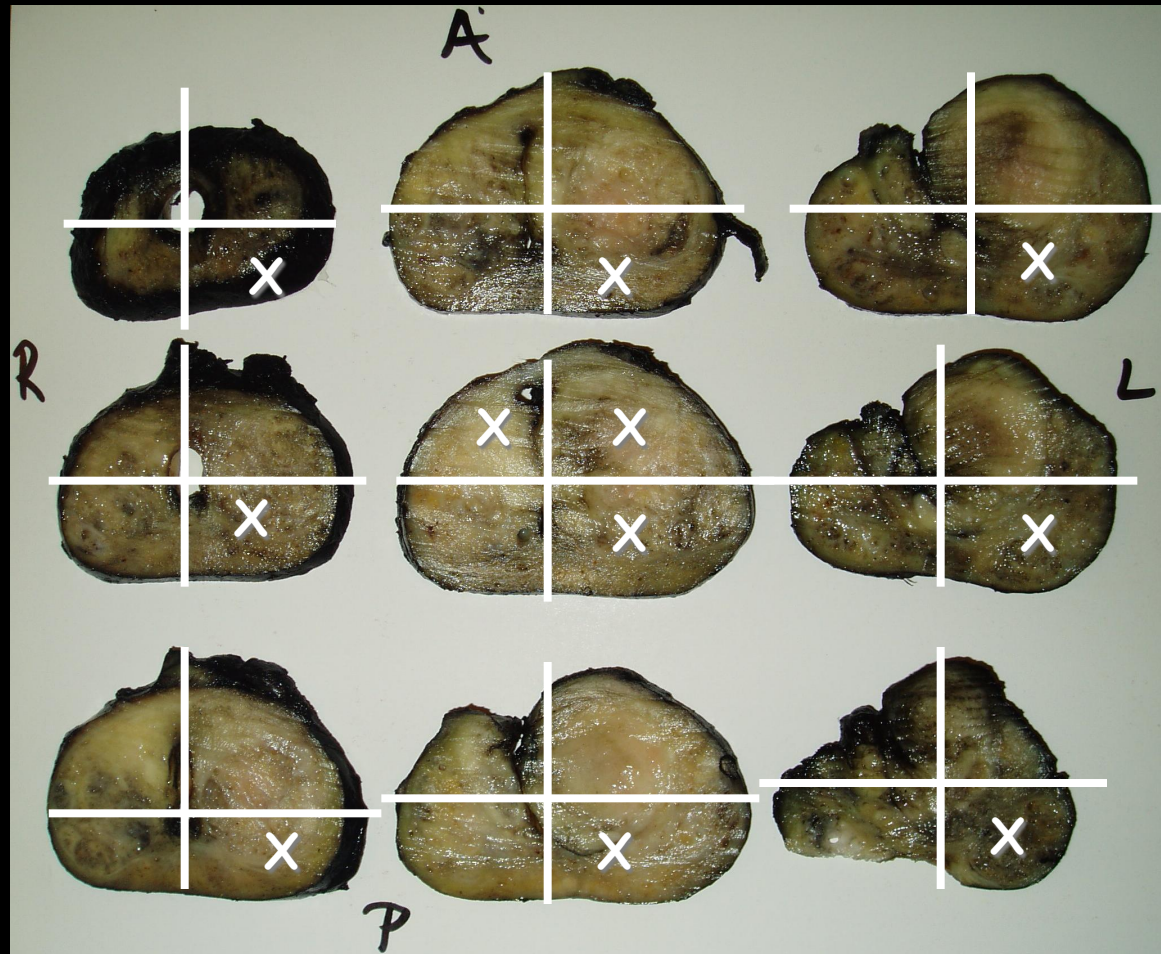
6: Atlamalı Posterior Kesitler + Anterior B



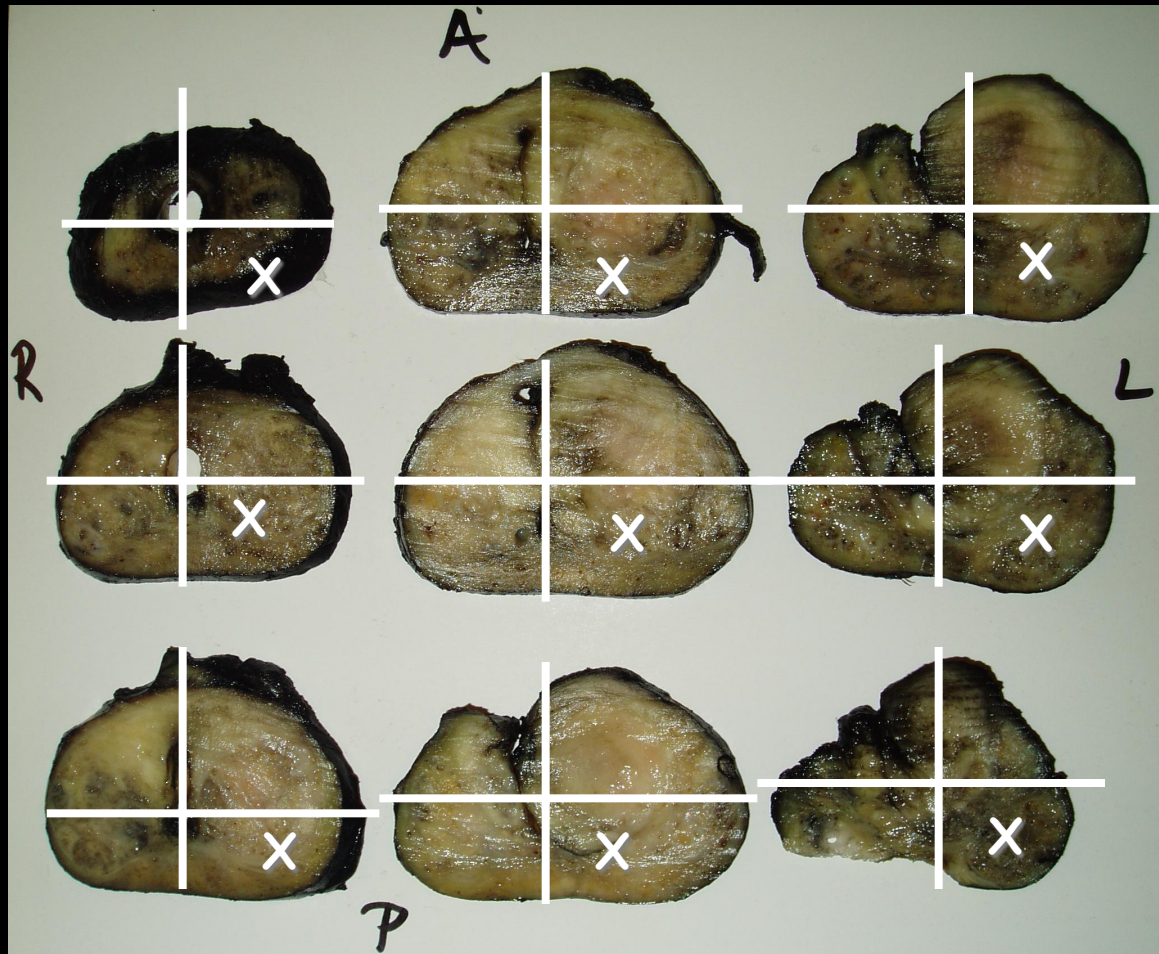
7: Tek taraf Posterior Kesitler



8: Tek taraf Posterior Kesitler + Anterior A



9: Tek taraf Posterior Kesitler + Anterior B



		$G \geq 7$	CS +	EPE	Lam Sayısı
1	Tüm posterior	92	86	84	23 (14-37)
2	Tüm posterior + Ant A	98	100	96	27 (16-49)
3	Tüm posterior + Ant B	94	86	91	26 (15-49)
4	Atlamalı posterior	83	71	62	15 (10-21)
5	Atlamalı post + Ant A	94	86	76	19 (12-37)
6	Atlamalı post + Ant B	89	71	69	17 (10-37)
7	Tek taraflı posterior	83	79	71	14 (10-36)
8	Tek taraflı post + Ant A	92	93	85	17 (10-36)
9	Tek taraflı post + Ant B	85	86	78	16 (9-36)
10	Tümü	100	100	100	34 (20-57)

		$G \geq 7$	CS +	EPE	Lam Sayısı
1	Tüm posterior	92	86	84	23 (14-37)
2	Tüm posterior + Ant A	98	100	96	27 (16-49)
3	Tüm posterior + Ant B	94	86	91	26 (15-49)
4	Atlamalı posterior	83	71	62	15 (10-21)
5	Atlamalı post + Ant A	94	86	76	19 (12-37)
6	Atlamalı post + Ant B	89	71	69	17 (10-37)
7	Tek taraflı posterior	83	79	71	14 (10-36)
8	Tek taraflı post + Ant A	92	93	85	17 (10-36)
9	Tek taraflı post + Ant B	85	86	78	16 (9-36)
10	Tümü	100	100	100	34 (20-57)

PARSİYEL

- Proksimal (mesane boynu) cerrahi sınır
- Distal (apikal) cerrahi sınır
- Vezikula seminalis tabanı
- İlk apikal kesitin tümü
- Makroskopik lezyonlar

- Ortalama 13 blok (7-36)
- EPE: %91, CS: %96

PARSİYEL

- Tüm makroskopik lezyonlar + alternatif kesitler
- EPE: %85

PARSİYEL (MAYO)

- Apikal cerrahi sınır
- Mesane boynu cerrahi sınırı
- Makroskopik tümörler CS içerir şekilde
- Apekteki ilk dilimin tümü
- Sonraki dilimlerin posterior 1/3'ü
- V. seminalis düzeyinde tüm dilim

Bostwick DG, Montironi R. Evaluating radical prostatectomy specimens: therapeutic and prognostic importance. *Virchows Arch* 430:1-16,1997.

Makroskopi

- **Ağırlık**
 - V. seminalisler hariç
- **Boyutlar**
 - 3 boyut
- **Tespit, çinileme**
- **Örnekleme**
 - Parsiyel yöntemi
- **Cerrahi sınırlar**
 - Apikal cerrahi sınır
 - Mesane boynu cerrahi sınırı

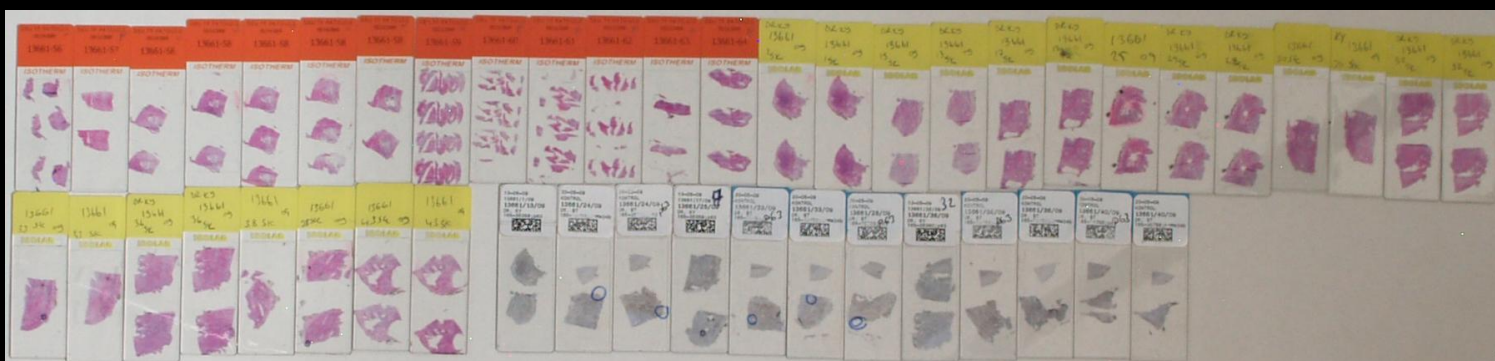
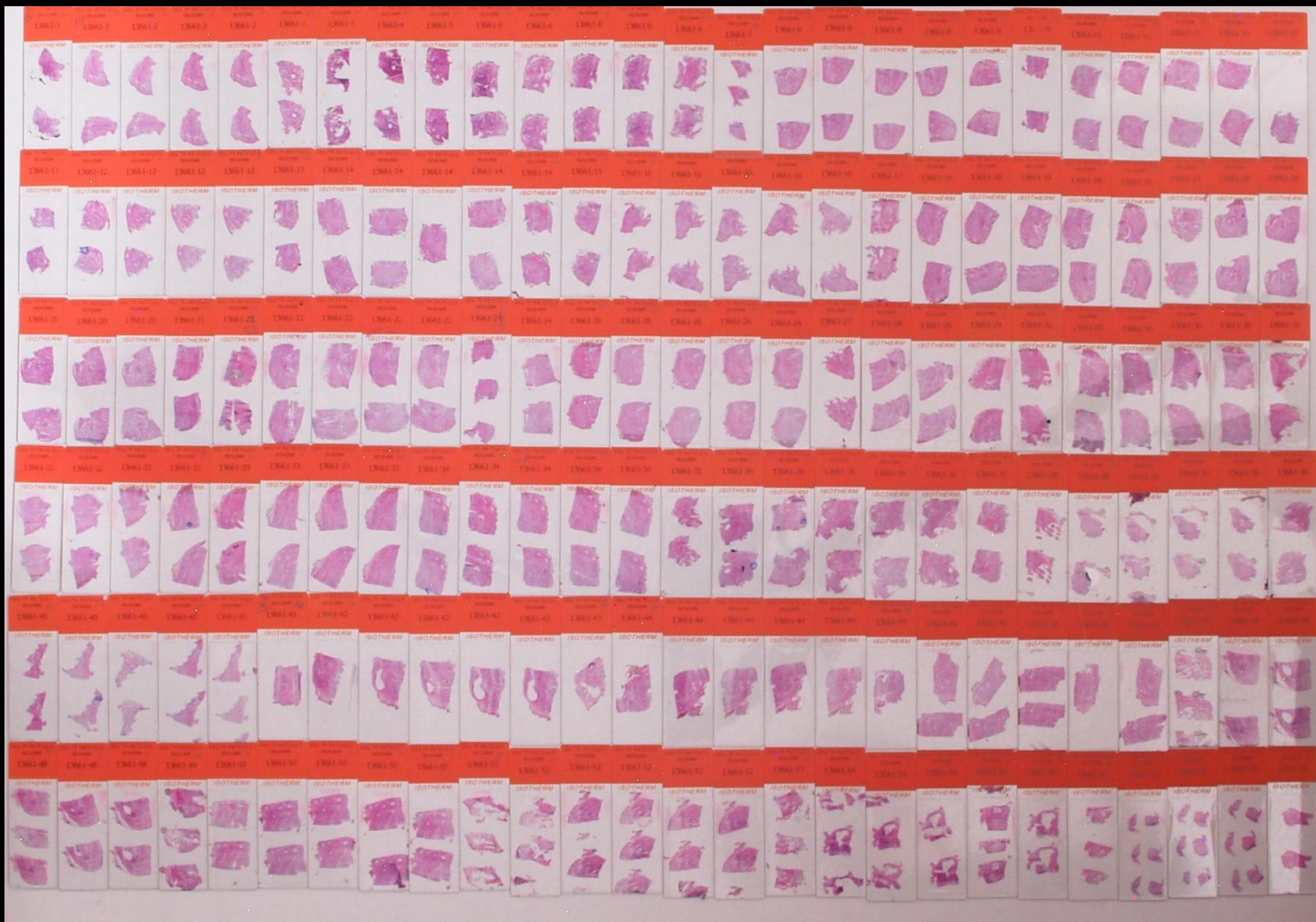


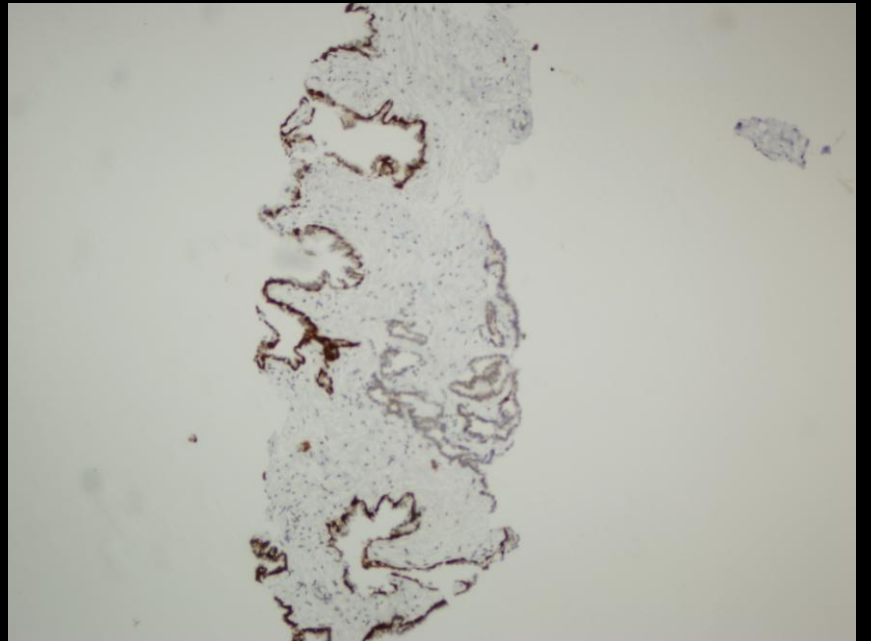
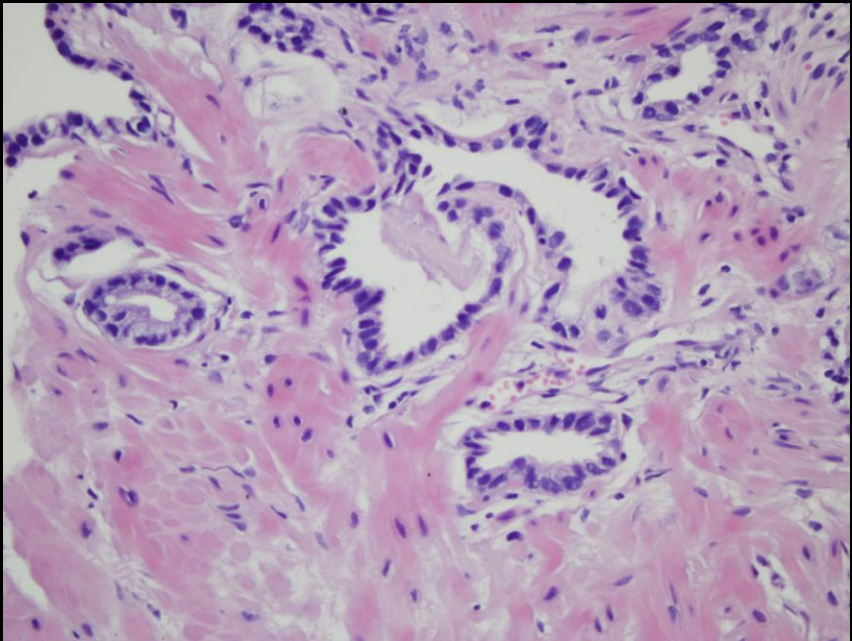
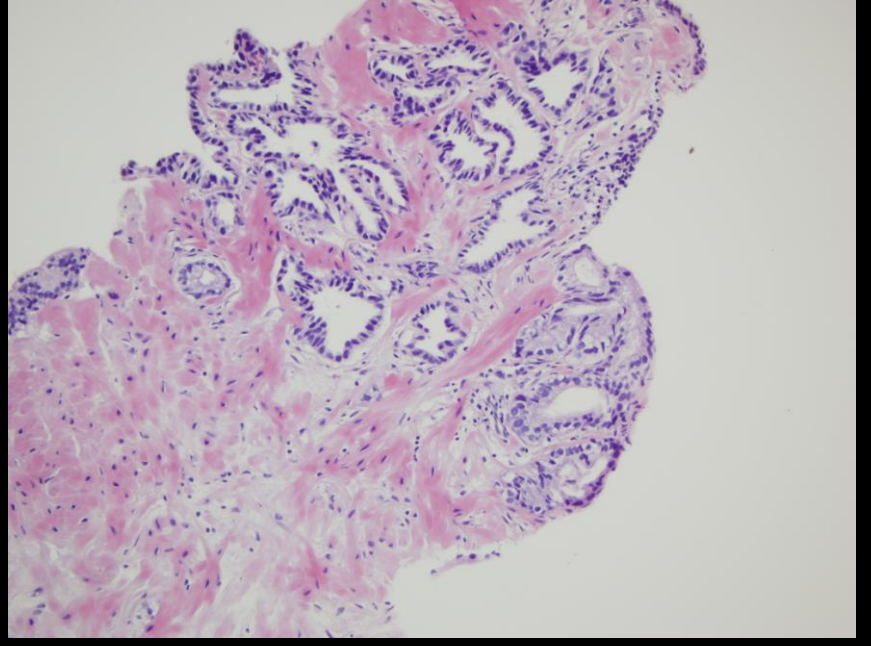
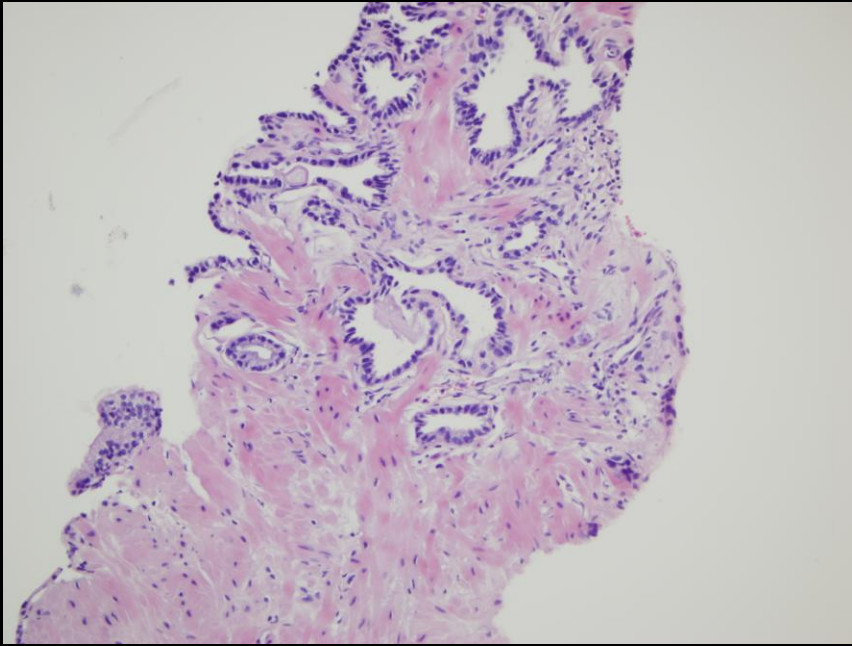
VANISHING CANCER

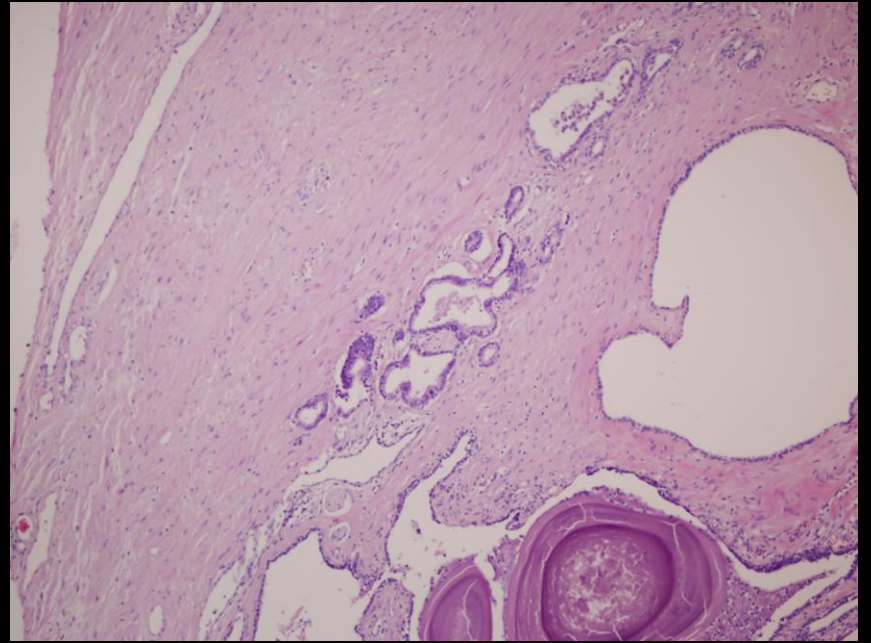
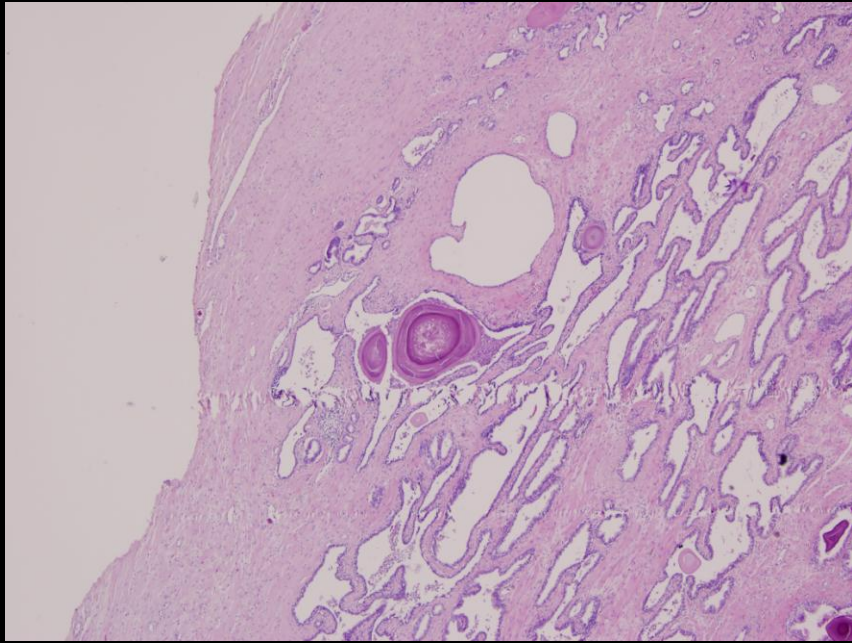- 0.01-0.13 cc
- %3-4
- %0.6

VANISHING CANCER

- Tümü takibe
- Biyopsi kontrolü
- Biyopside tümör olan taraftan YK
- Bloklardaki dokunun ters çevrilmesi-YK
- Kuşkulu odaklarda İHK
 - CK, p63, AMACR, PSA
- DNA finger printing

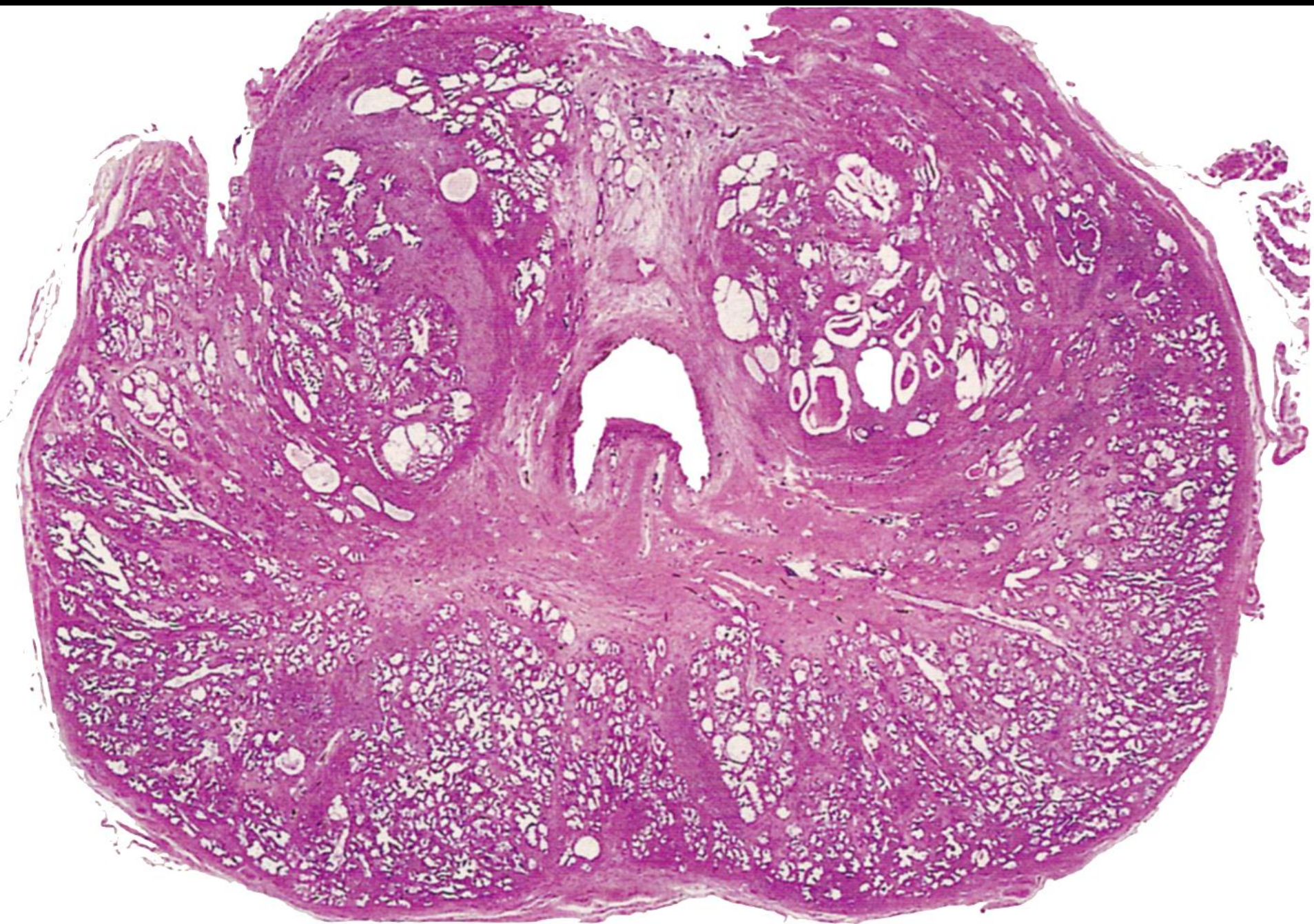


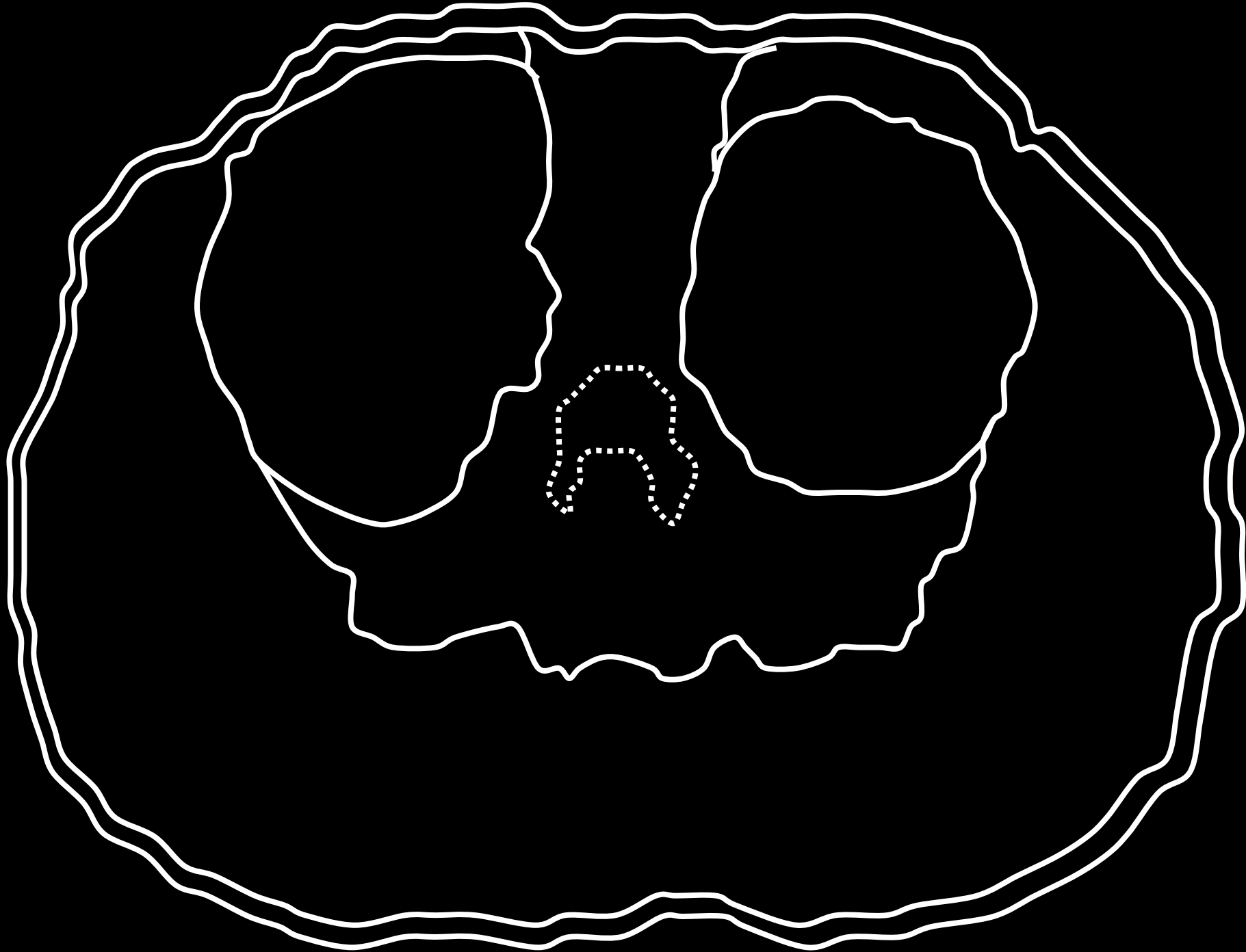


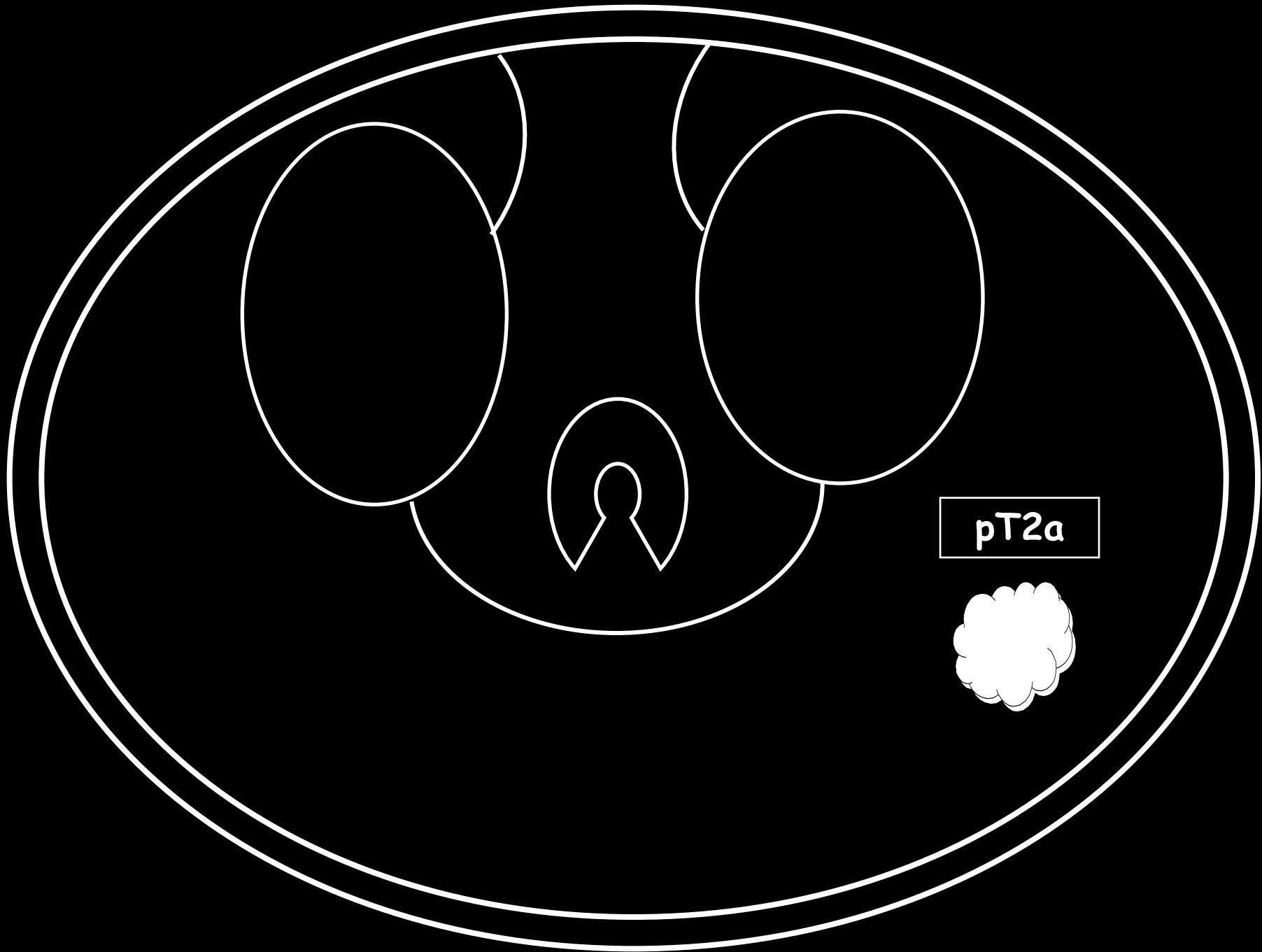





MIKROSKOPI

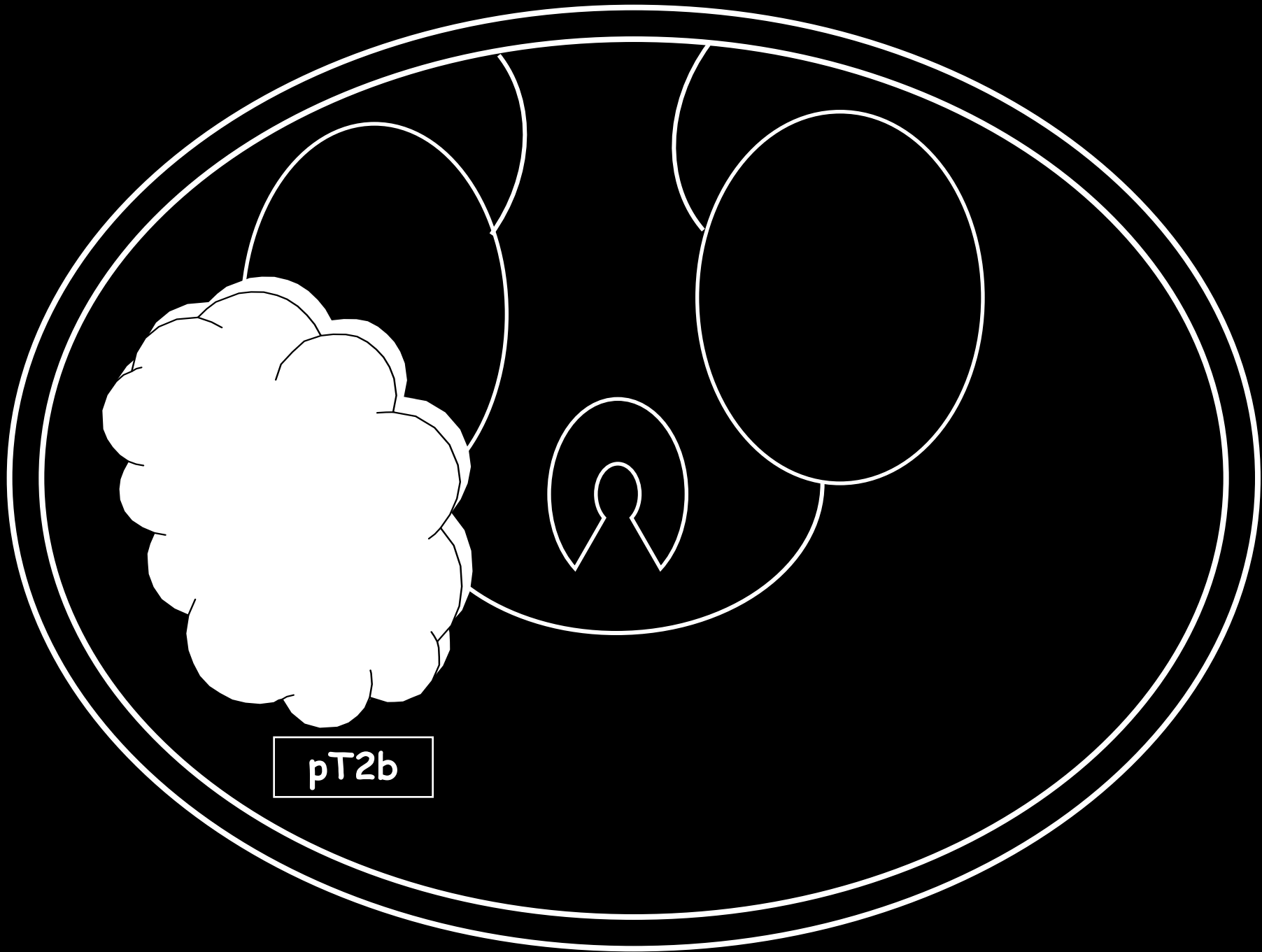




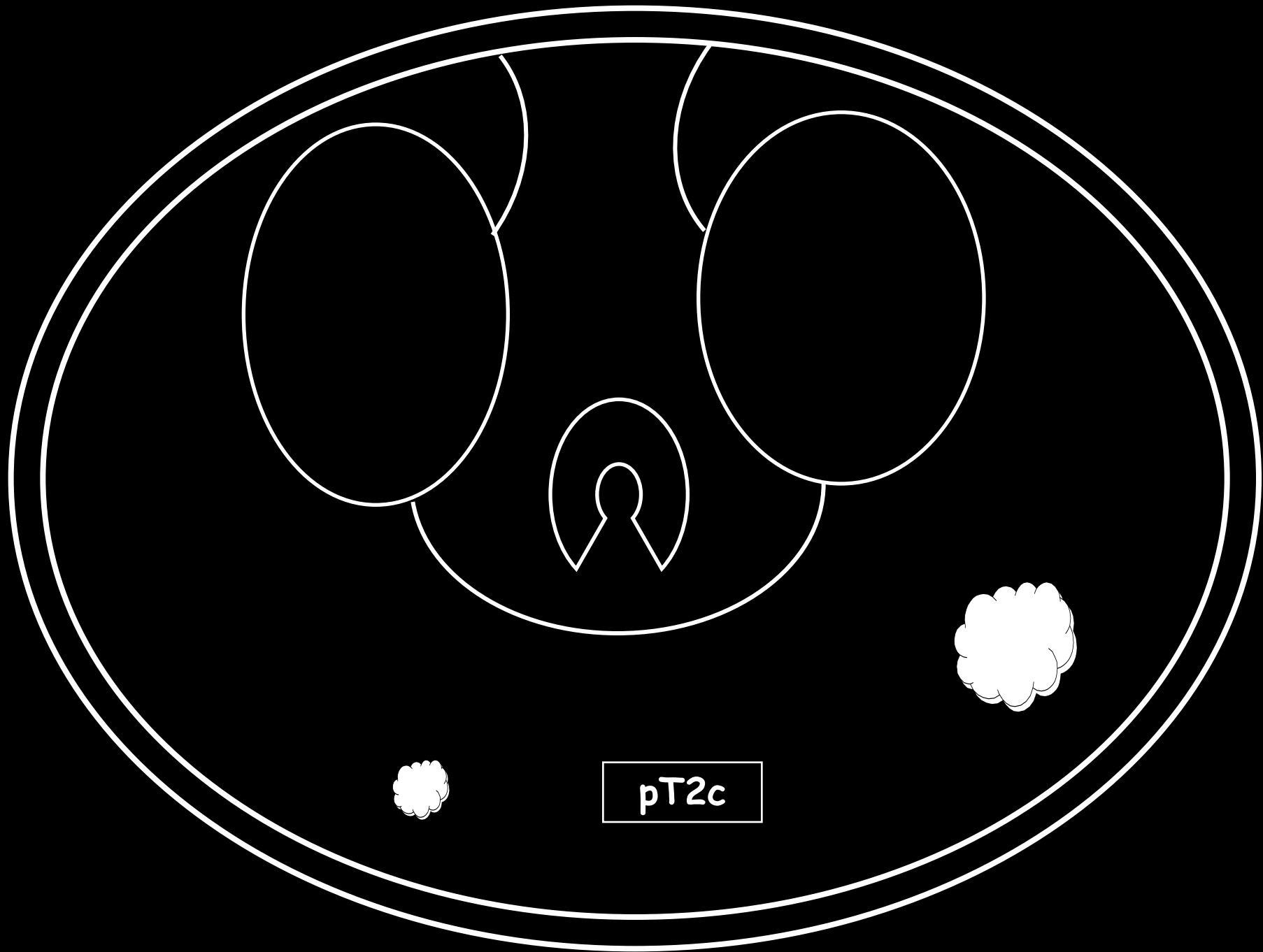


pT2a

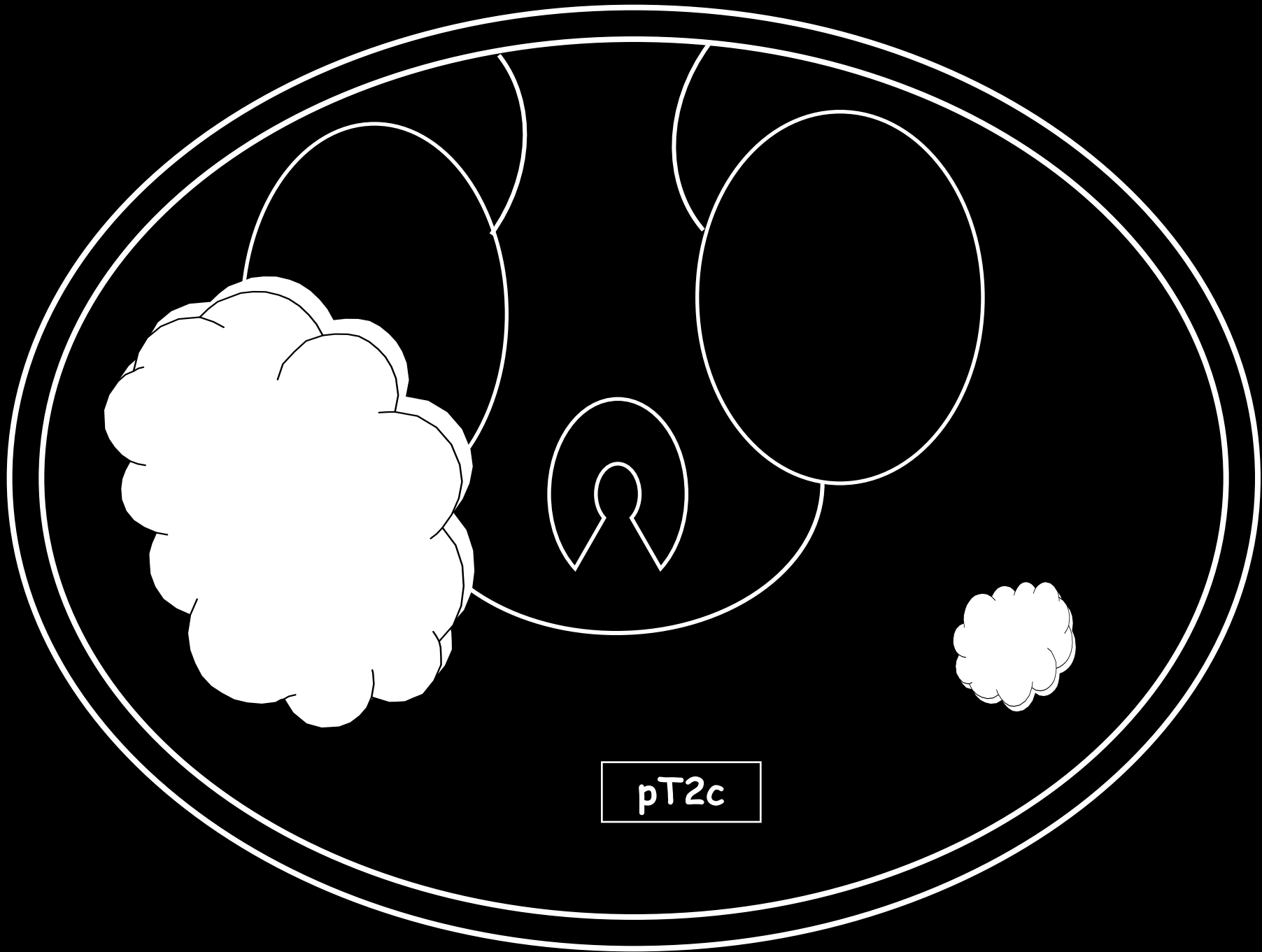




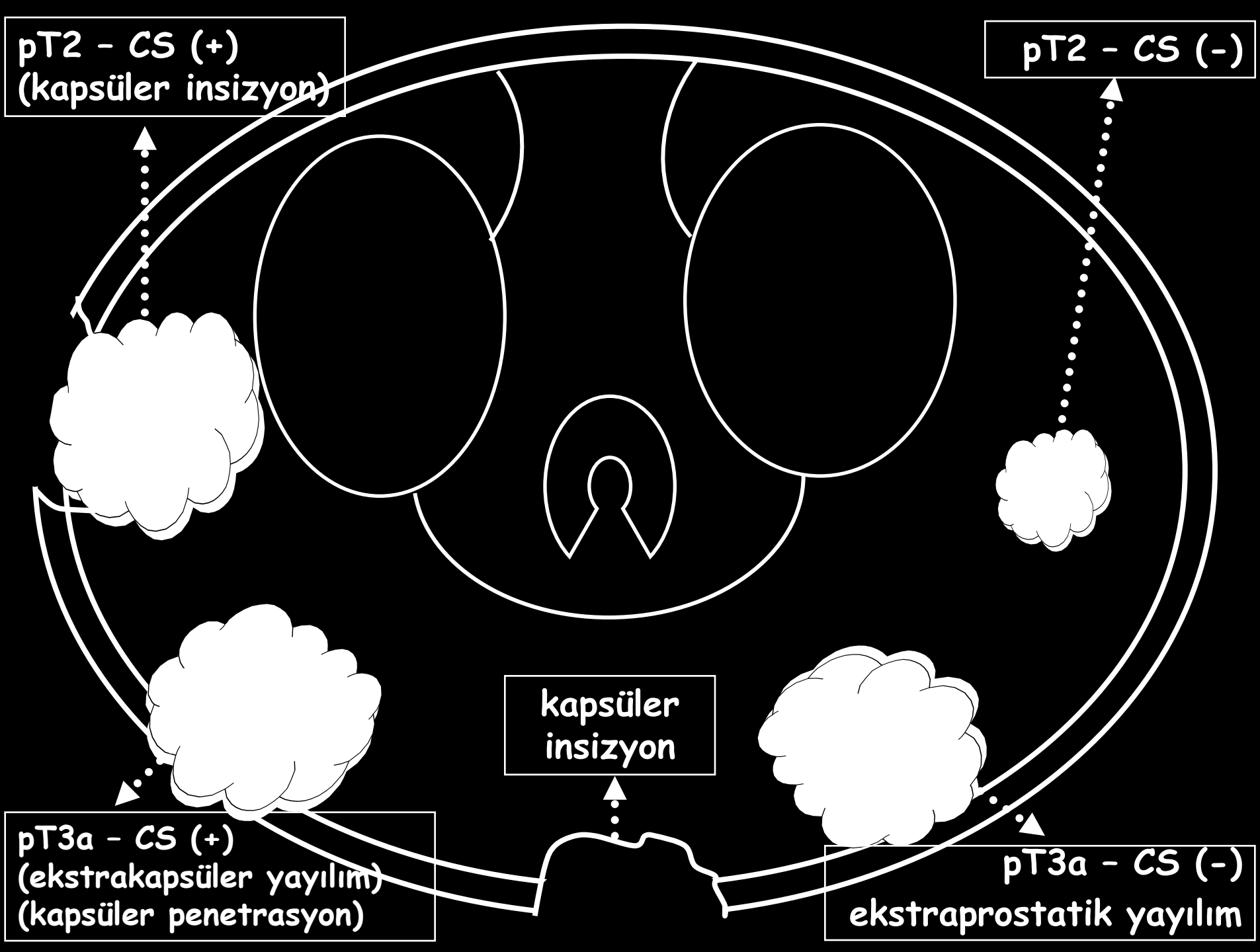
pT2b



pT2c

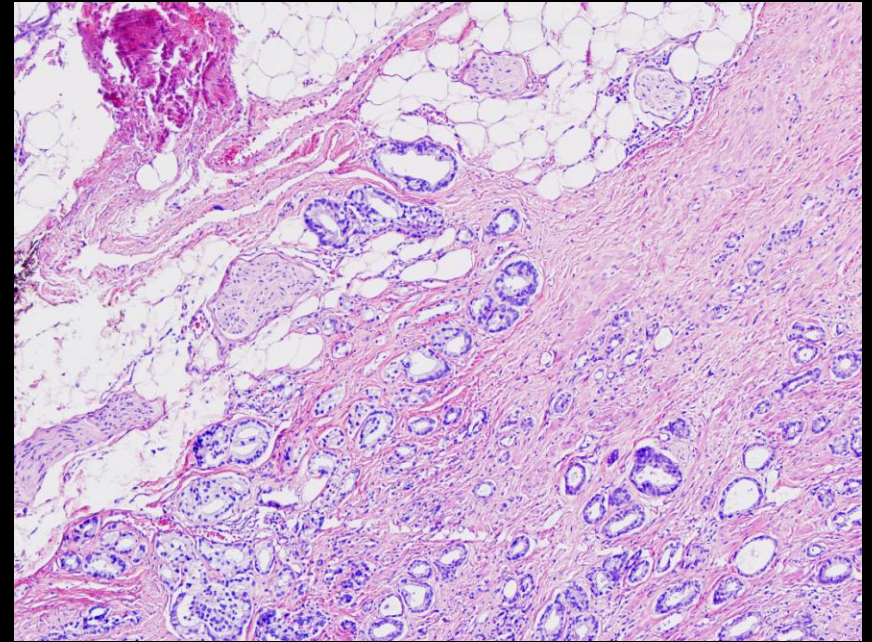
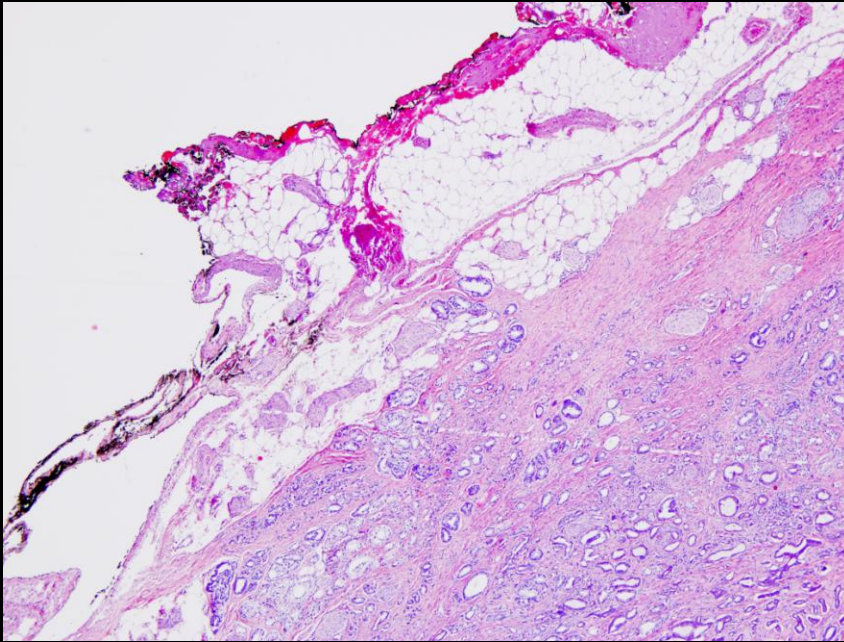


pT2c



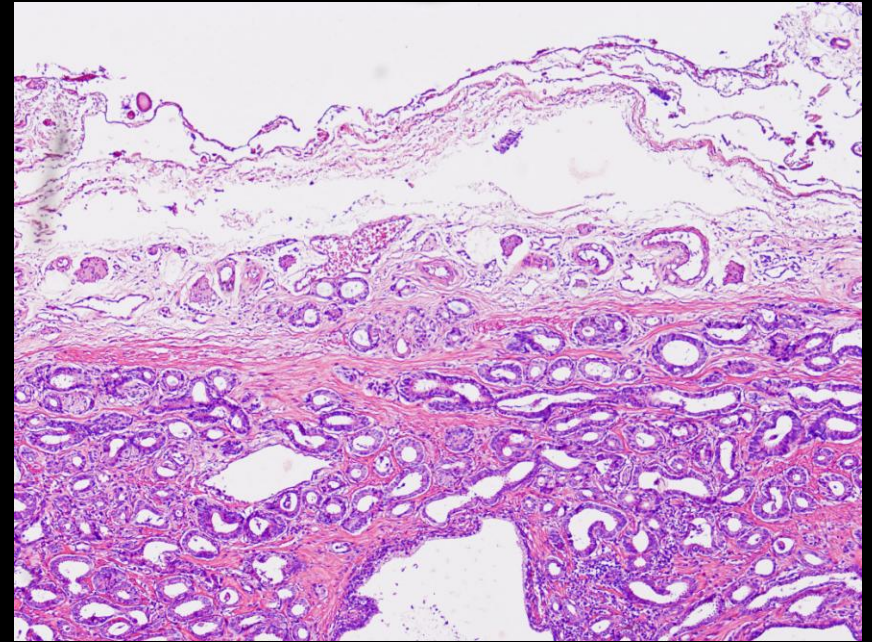
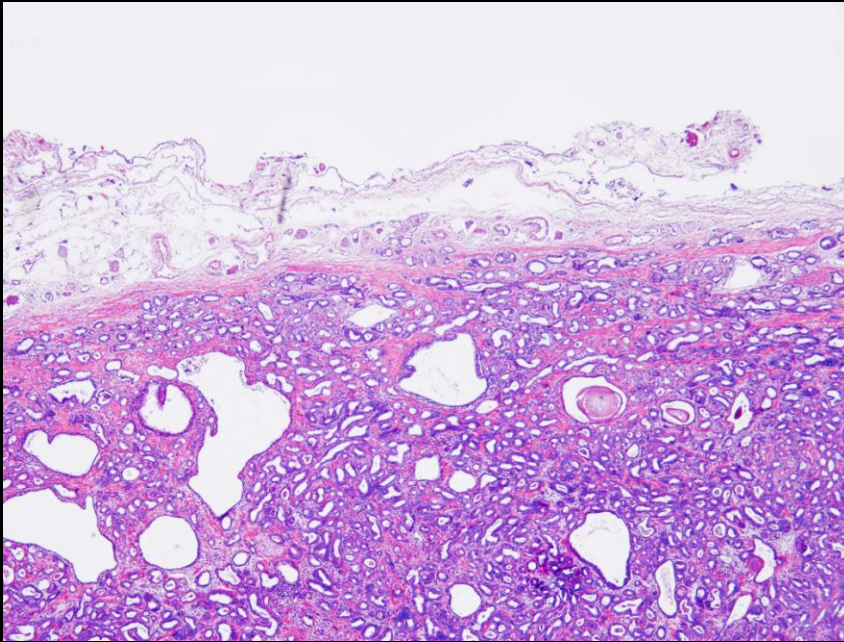
EKSTRAPROSTATİK YAYILIM

Posterior, posterolateral, lateral



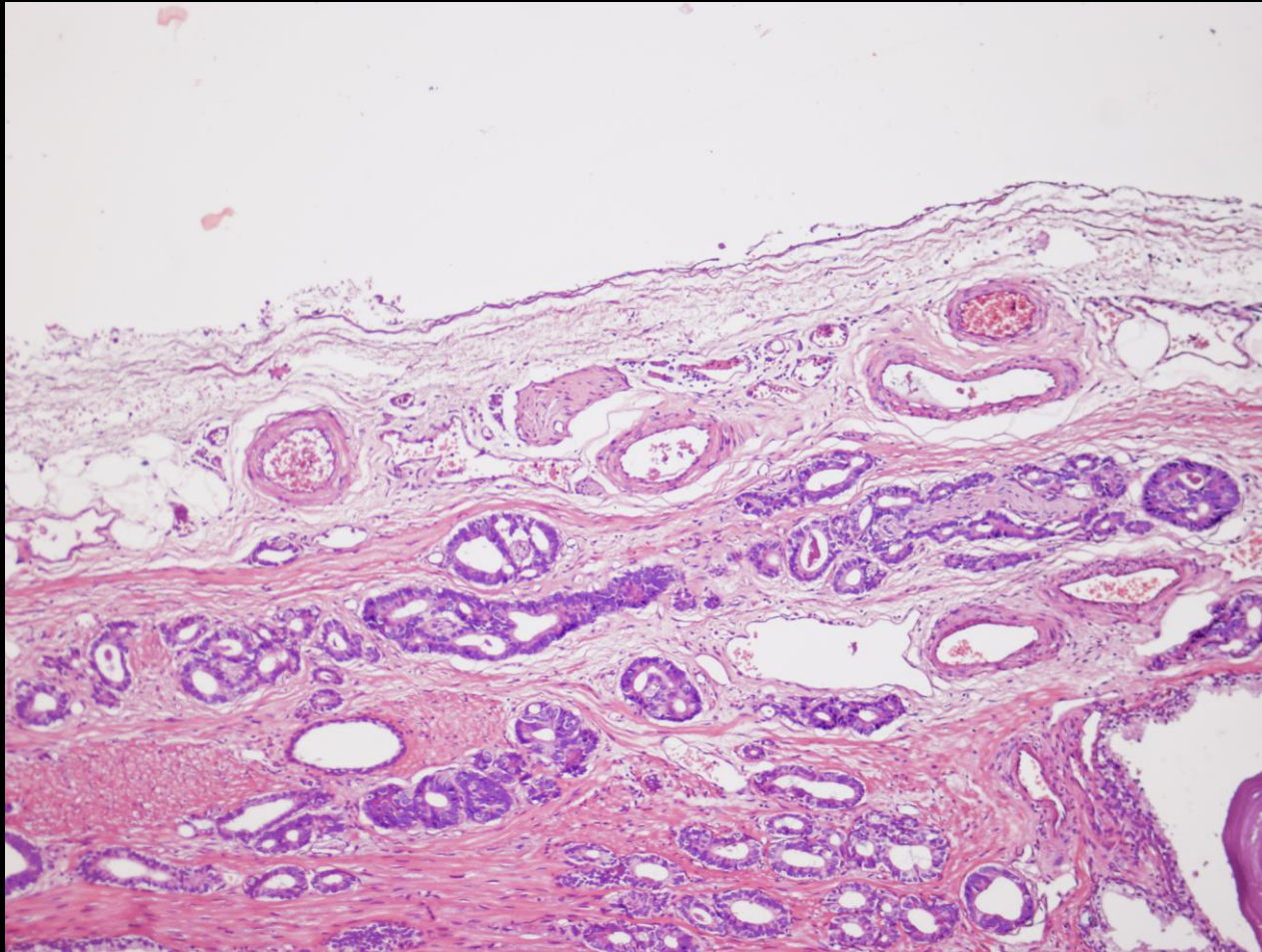
EKSTRAPROSTATİK YAYILIM

Posterior, posterolateral, lateral



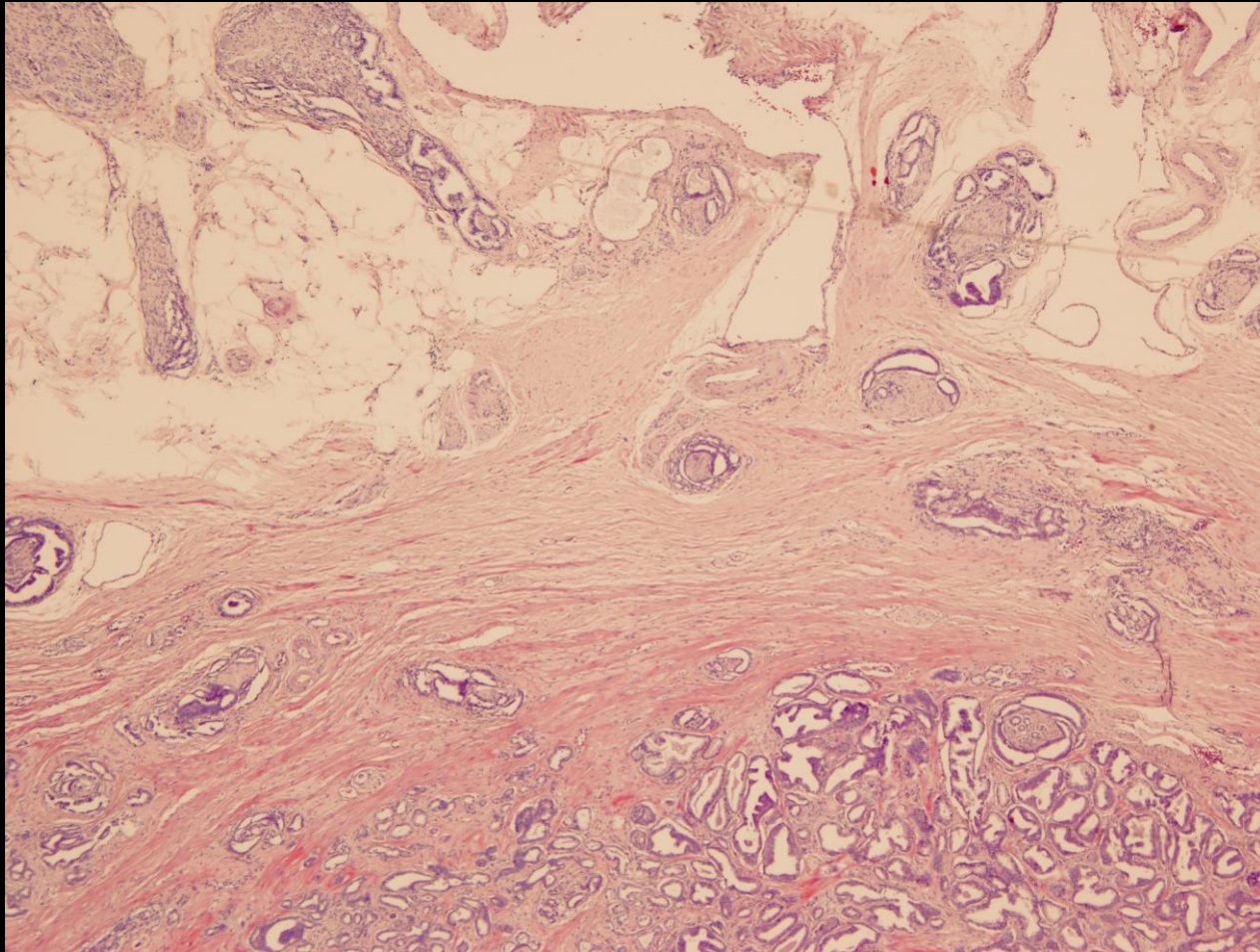
EKSTRAPROSTATİK YAYILIM

PNI



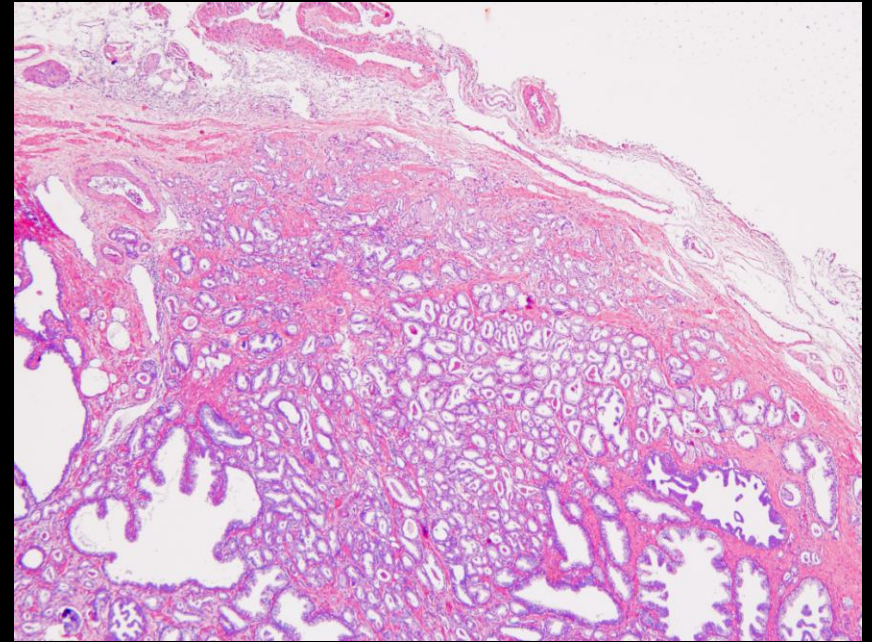
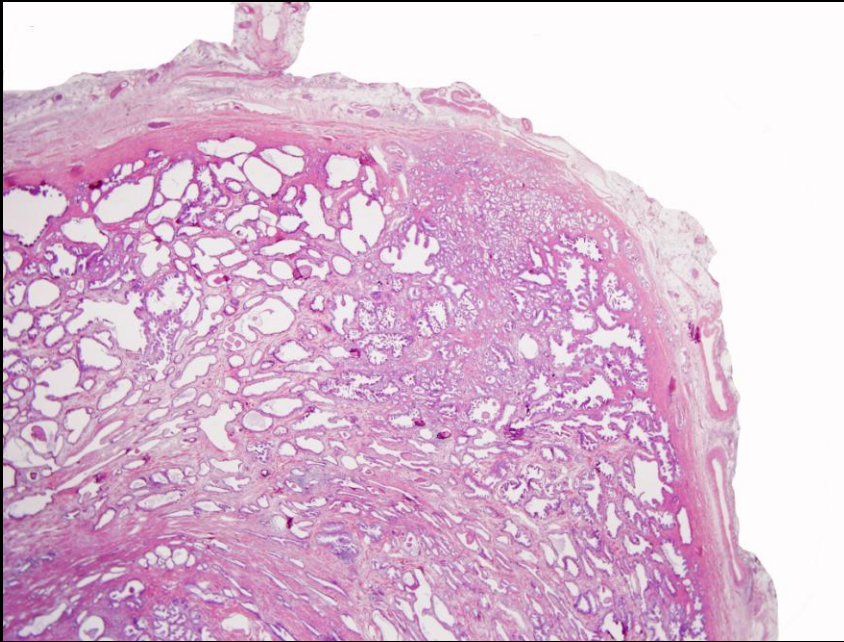
EKSTRAPROSTATİK YAYILIM

PNI



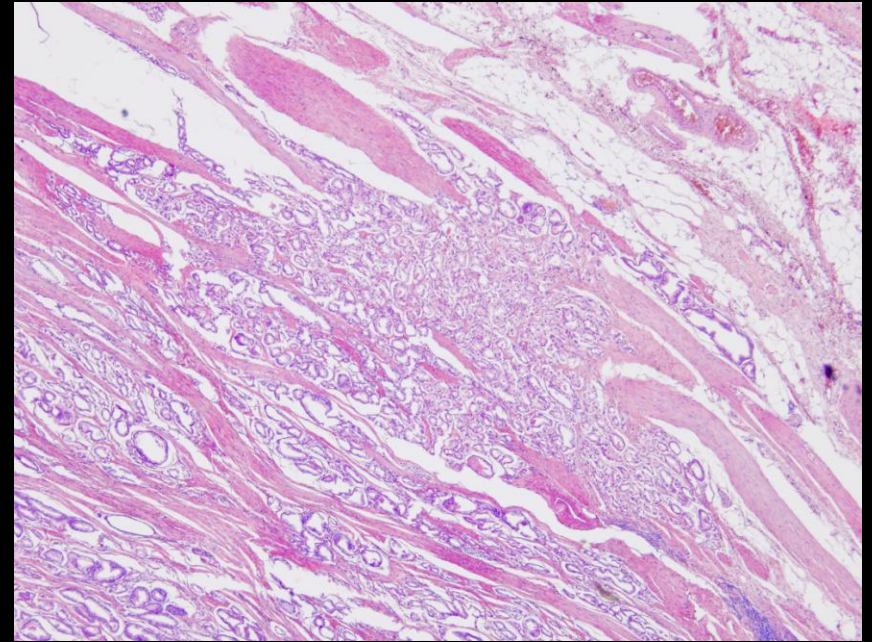
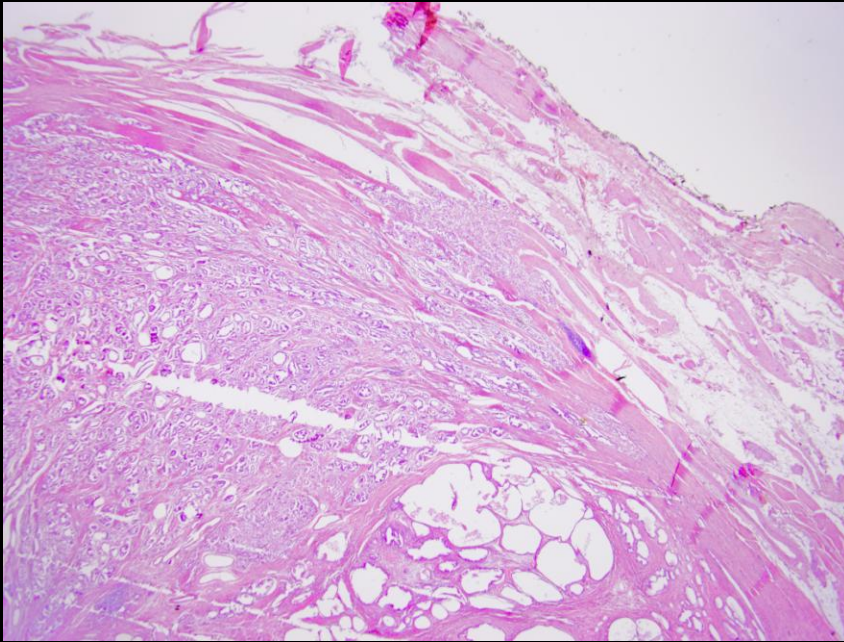
EKSTRAPROSTATİK YAYILIM

“bulging”



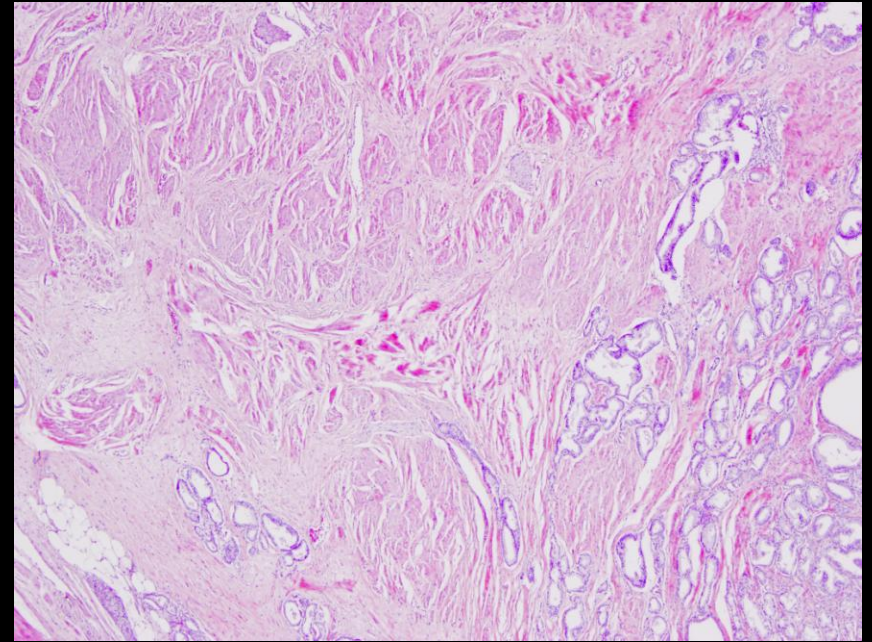
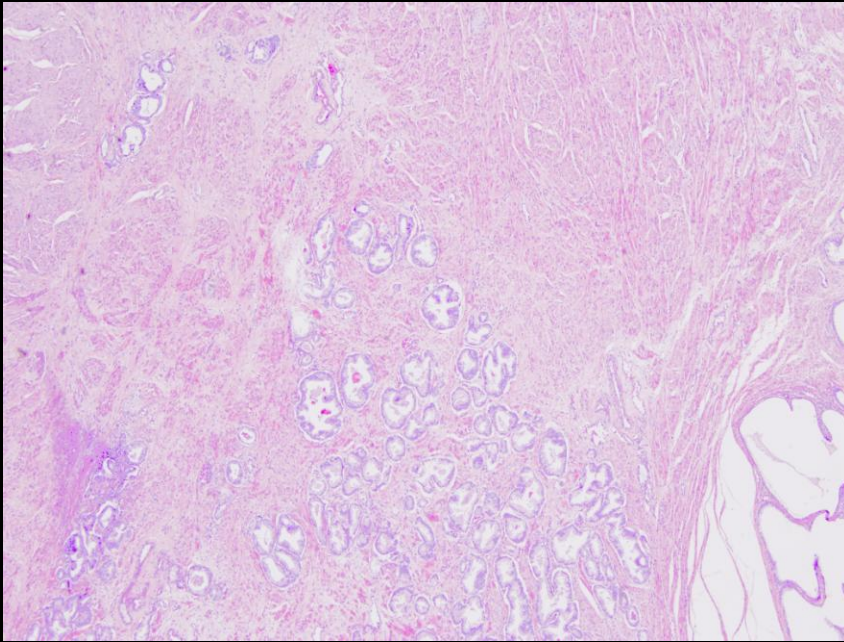
EKSTRAPROSTATİK YAYILIM

Anterior

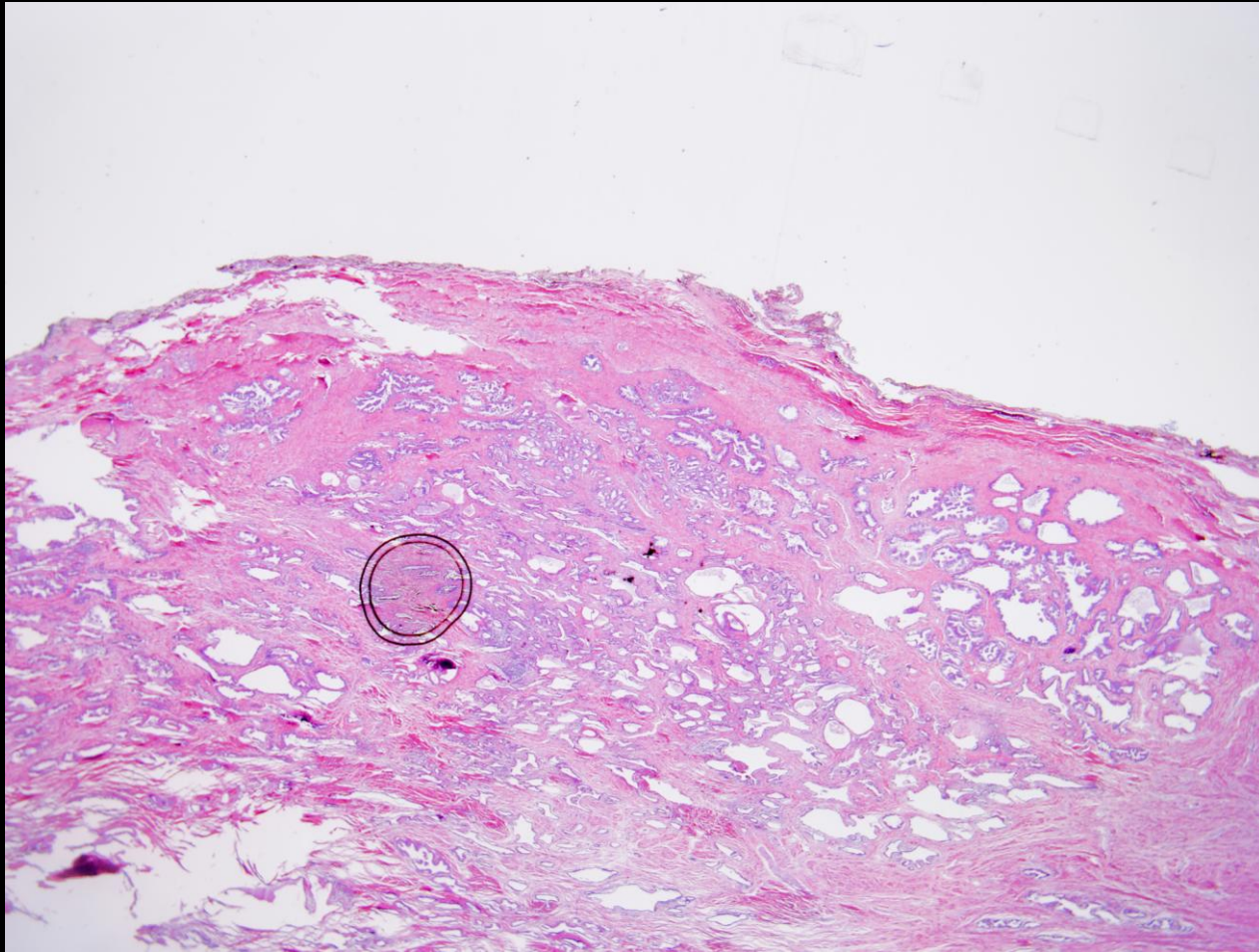


EKSTRAPROSTATİK YAYILIM

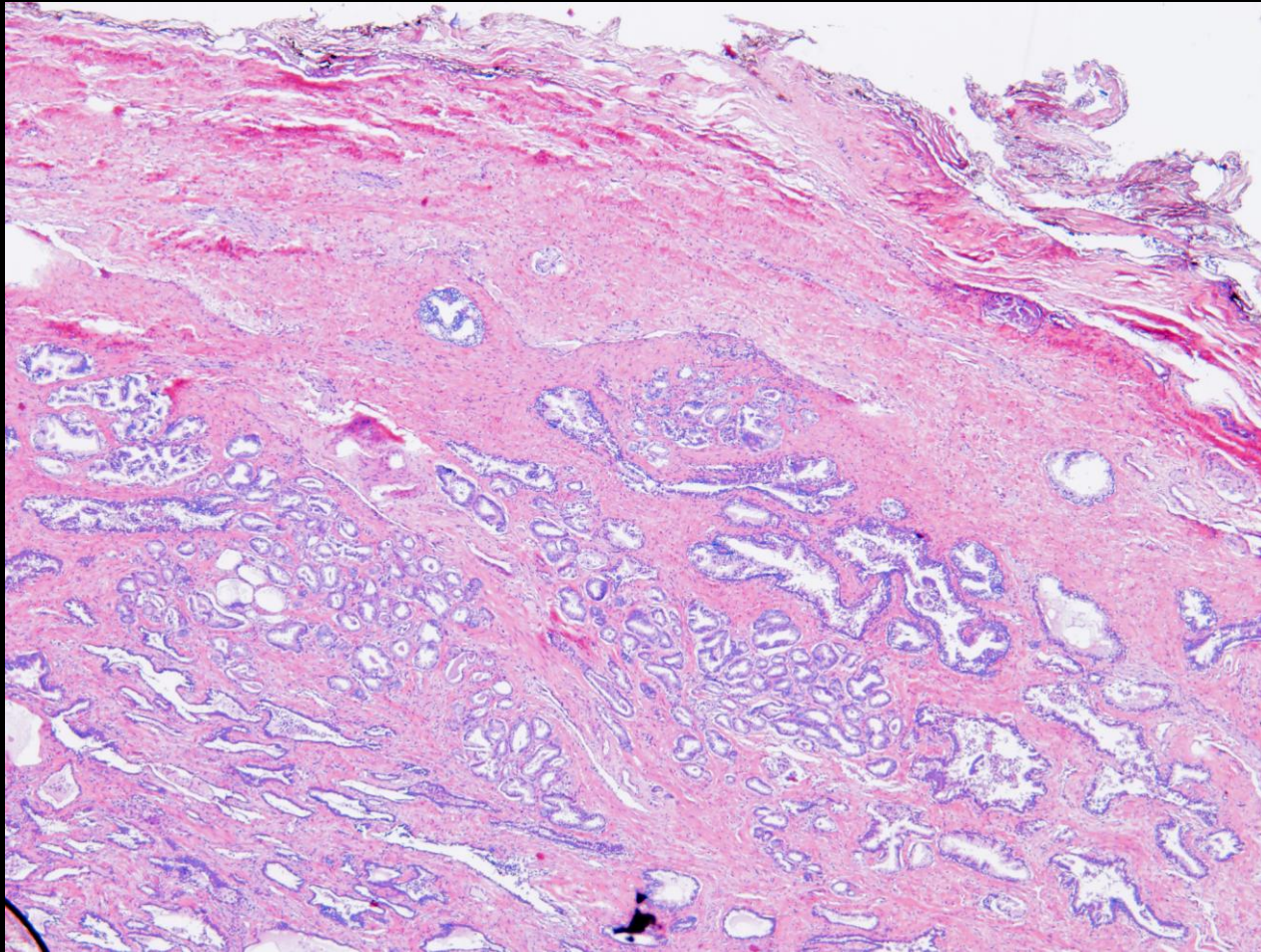
Mesane boynu



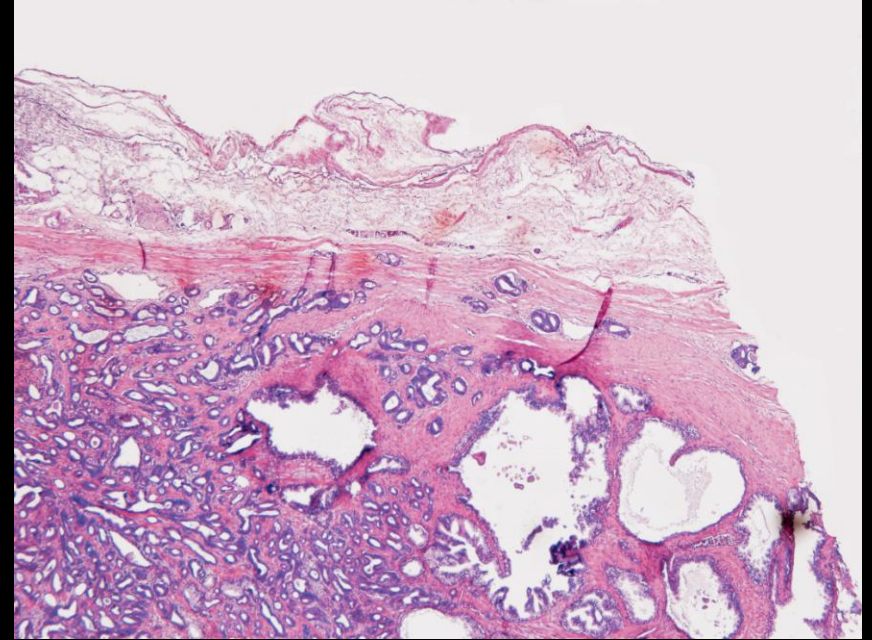
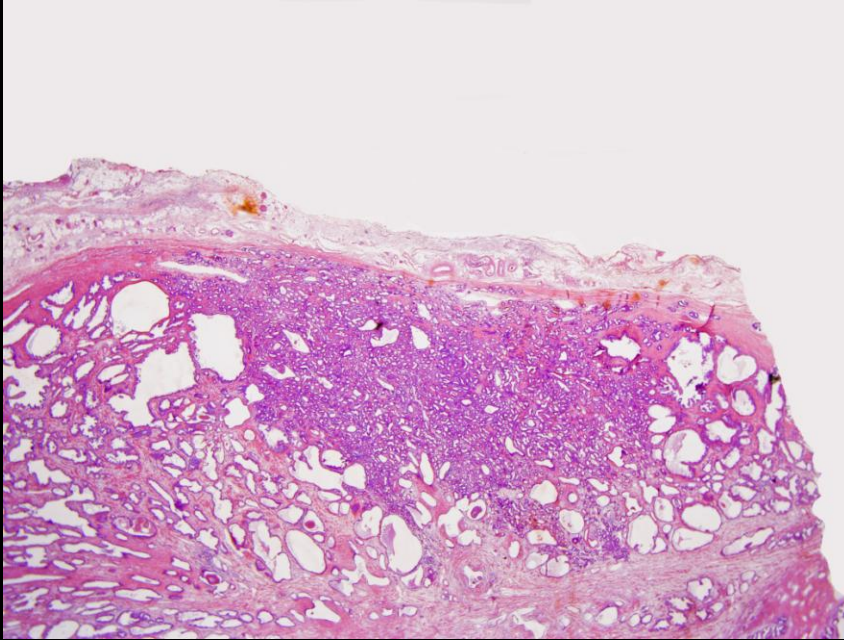
EKSTRAPROSTATİK YAYILIM?



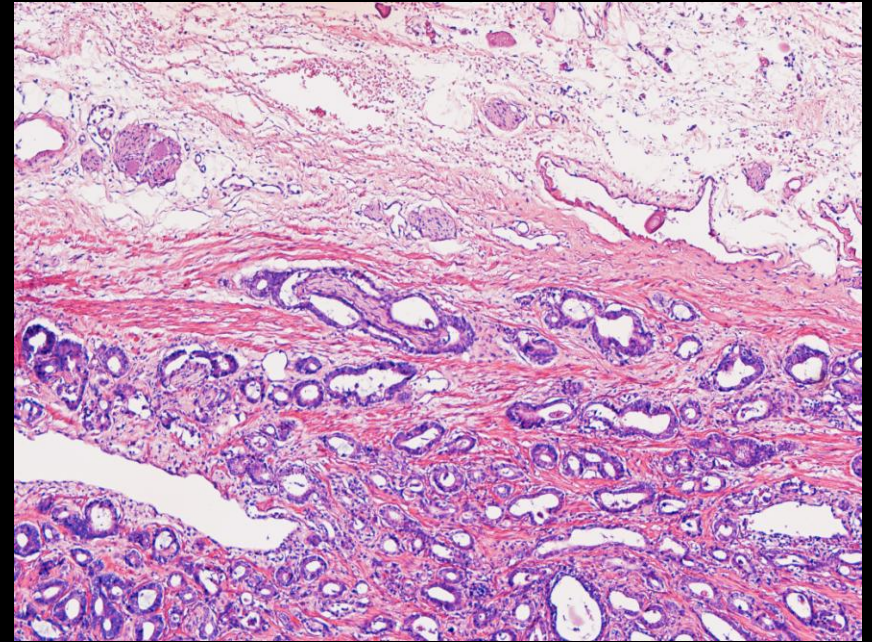
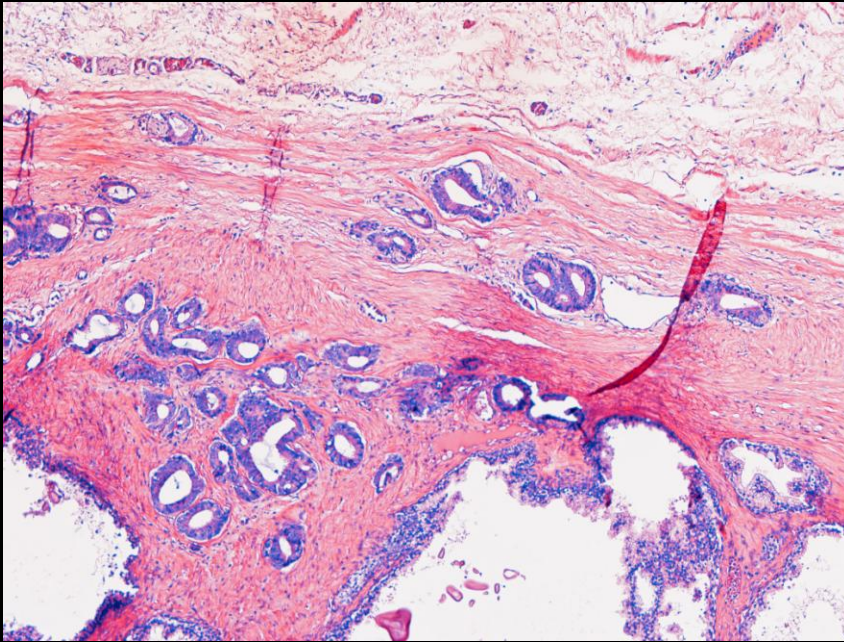
EKSTRAPROSTATİK YAYILIM?



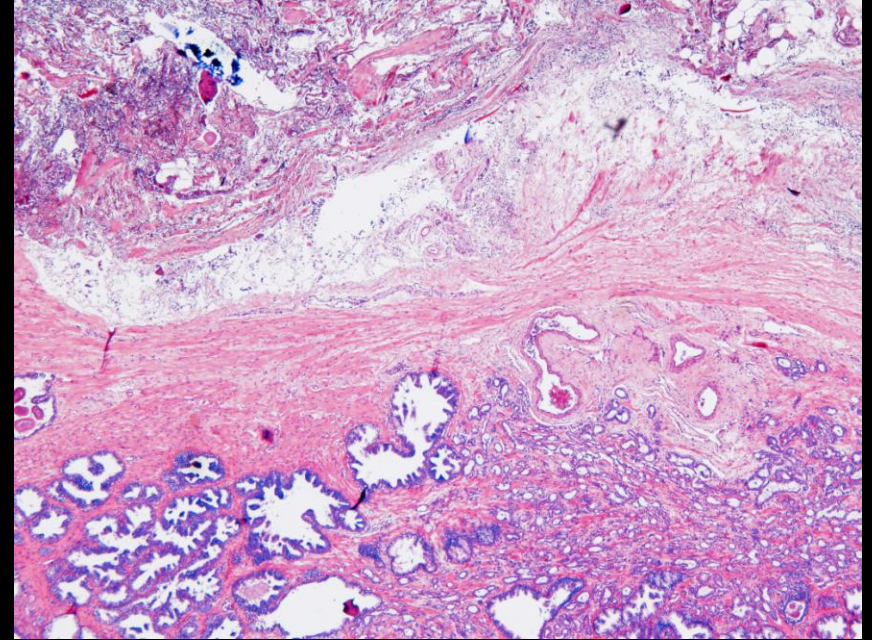
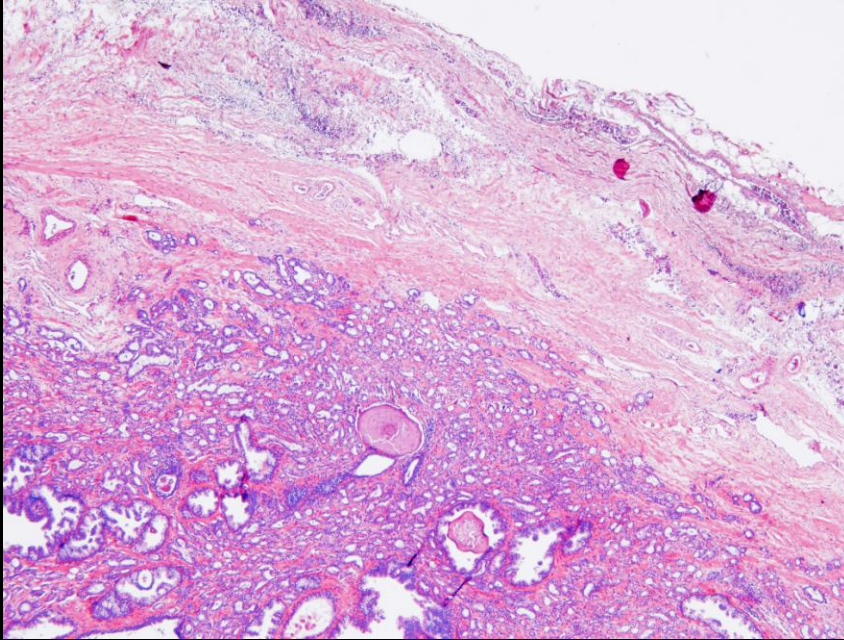
EKSTRAPROSTATİK YAYILIM?



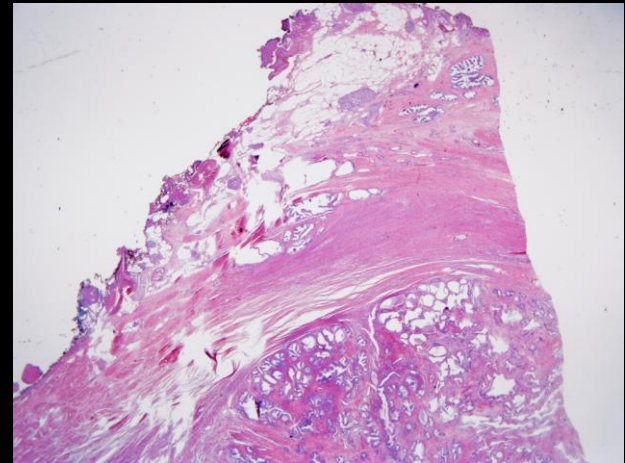
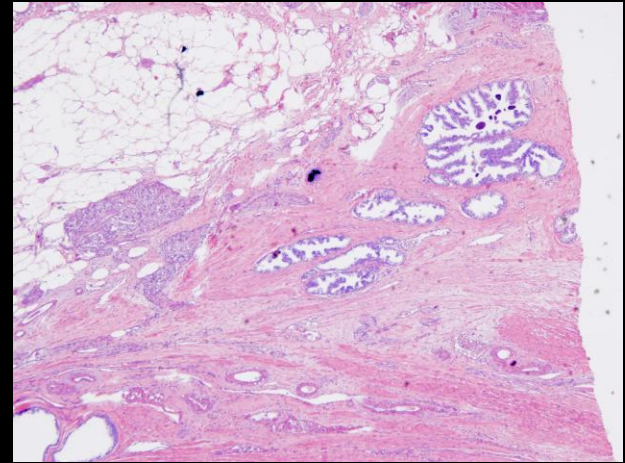
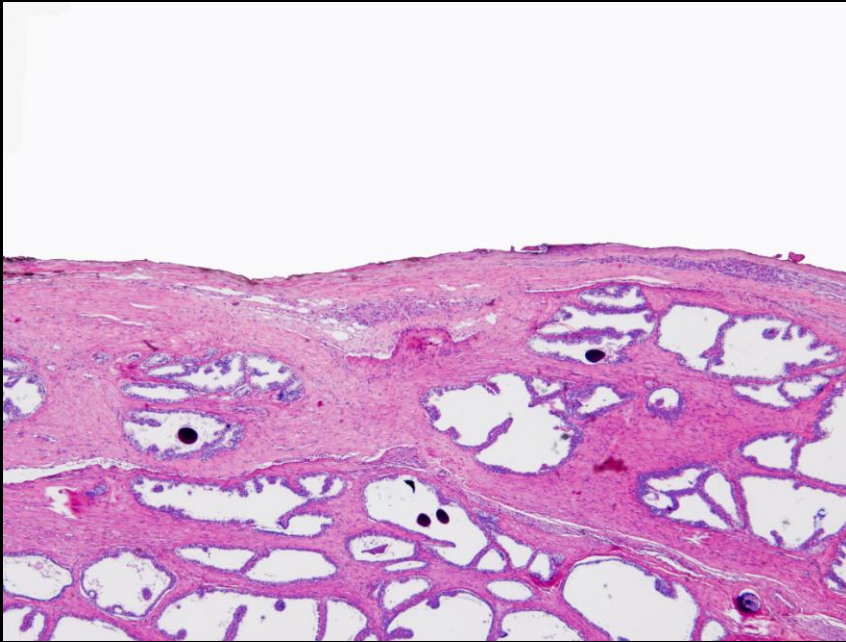
EKSTRAPROSTATİK YAYILIM?

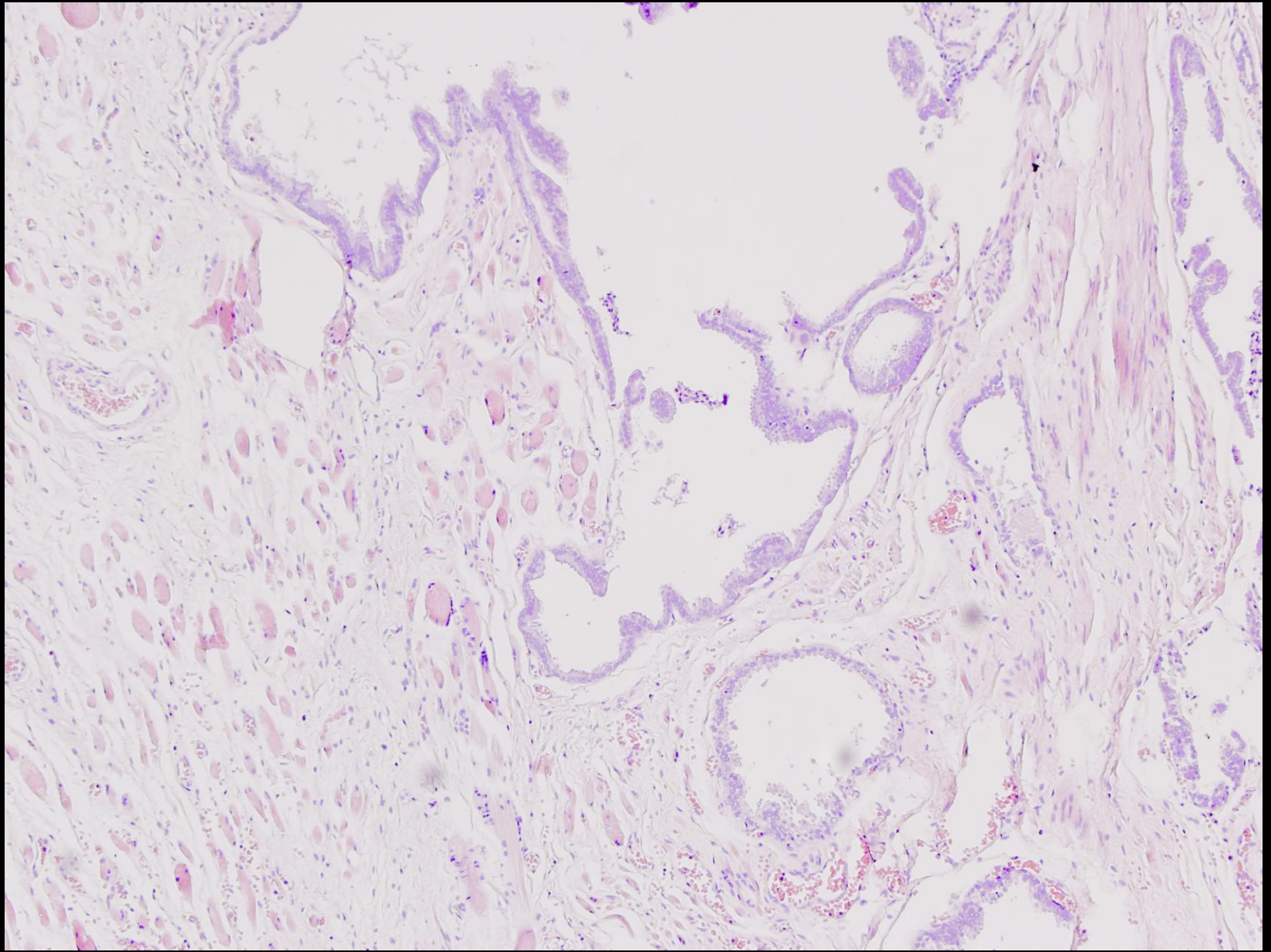


EKSTRAPROSTATİK YAYILIM?



EKSTRAPROSTATİK BEZ?





EKSTRAPROSTATİK YAYILIM

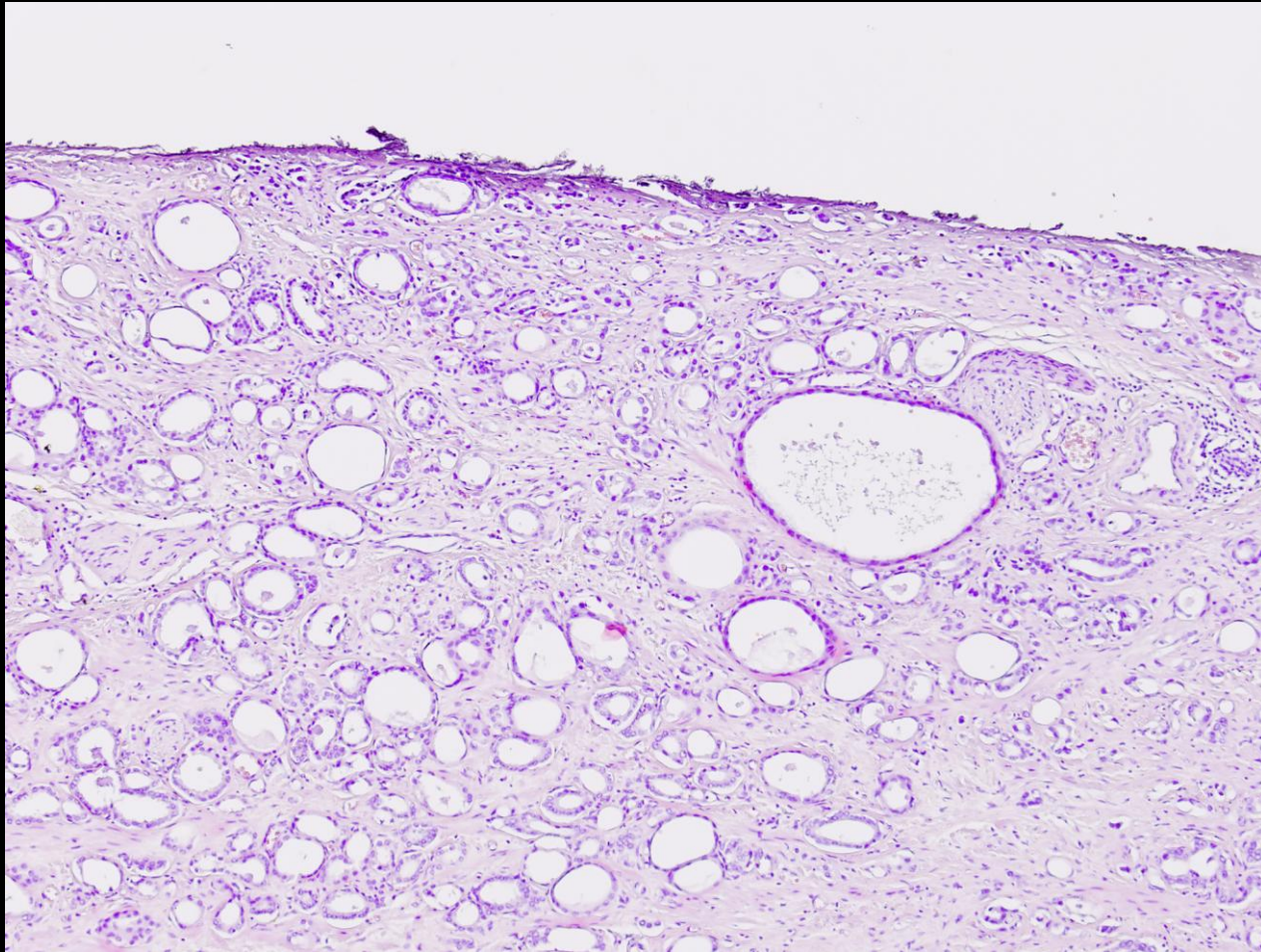
- Sağ veya sol
- Posterior
- Posterolateral
- Lateral
- Anterior
- Apikal
- Orta hat
- Mesane boynu

EKSTRAPROSTATİK YAYILIM

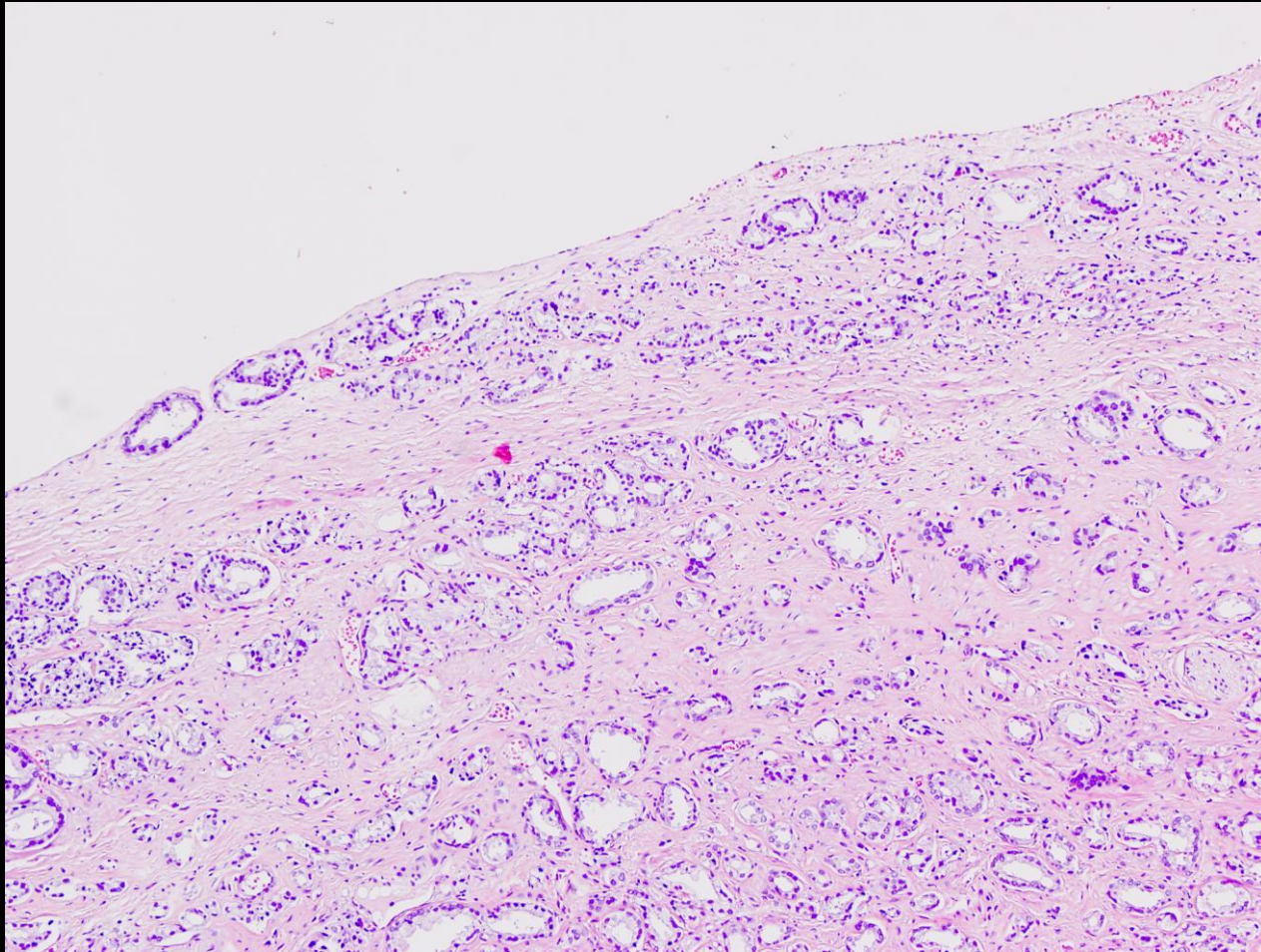
1. Bir kaç bezden ibaret ise fokal, daha fazla ise yaygın
2. 1 büyük büyütme alanından küçükse fokal, büyükse yaygın
3. Lineer veya radyal uzunluk ölçümü
4. Oküler mikrometre veya grid ile ölçüm



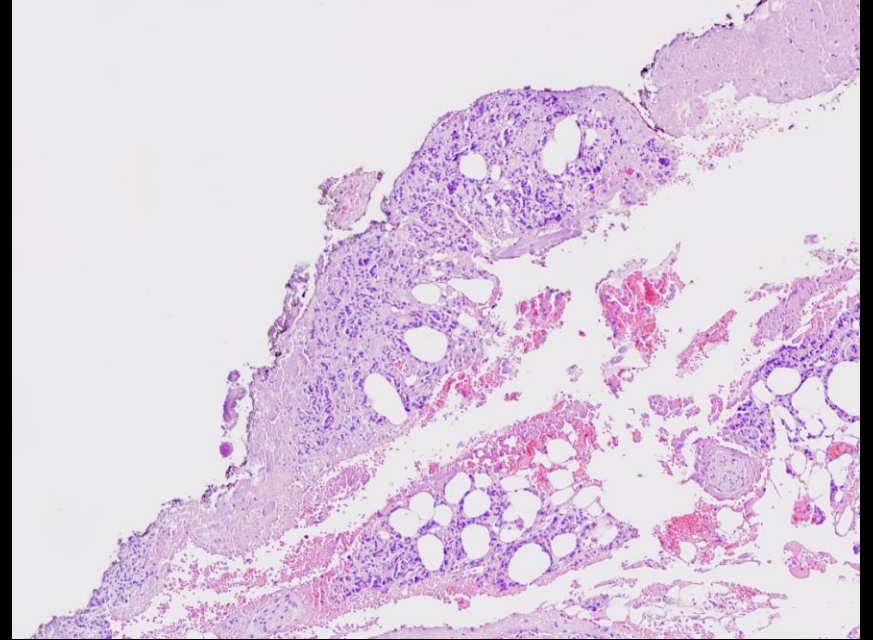
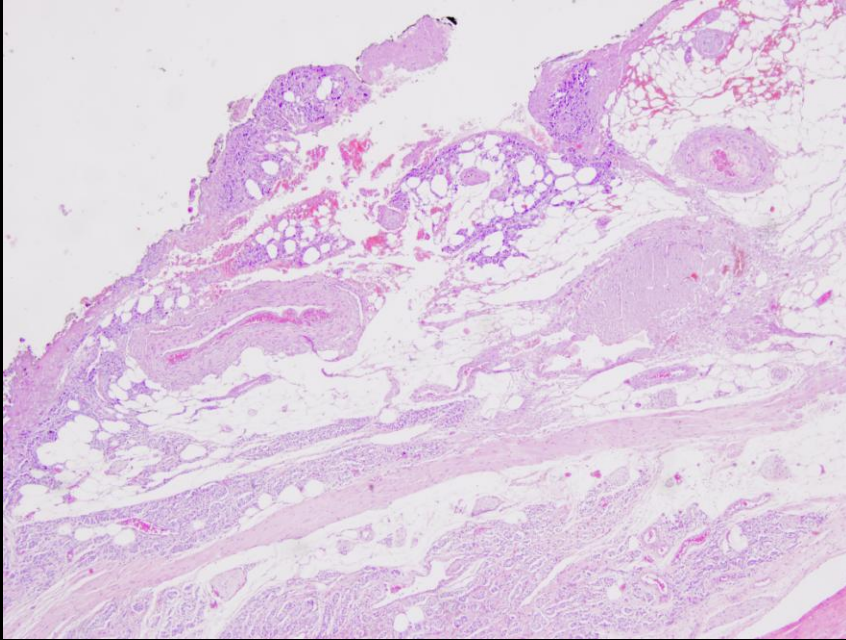
CERRAHI SINIR



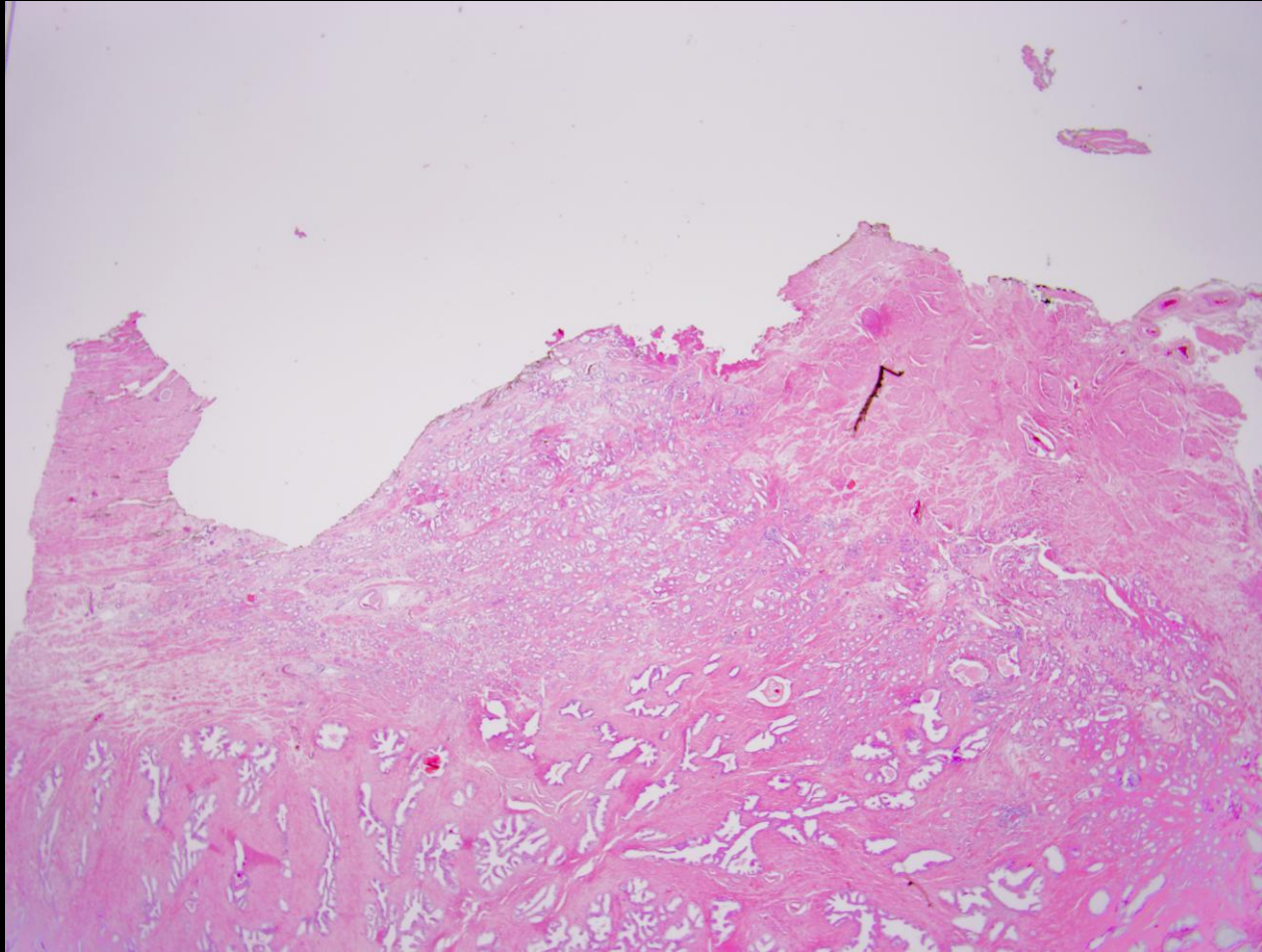
CERRAHI SINİR



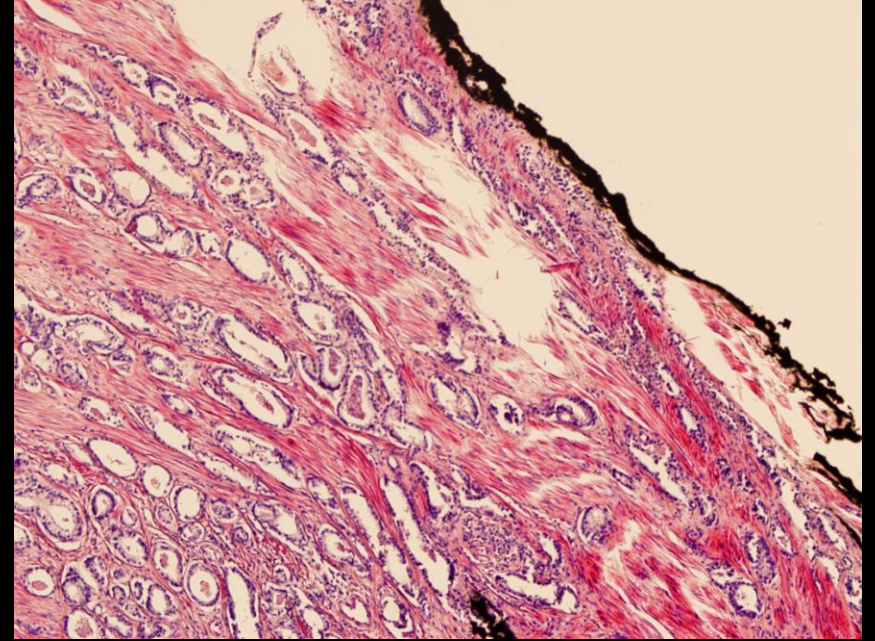
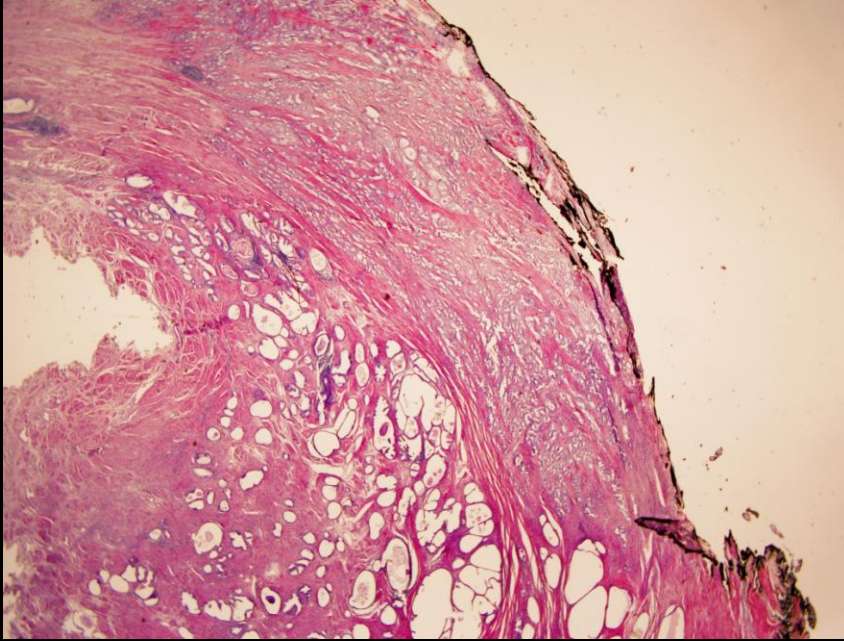
CERRAHI SINİR



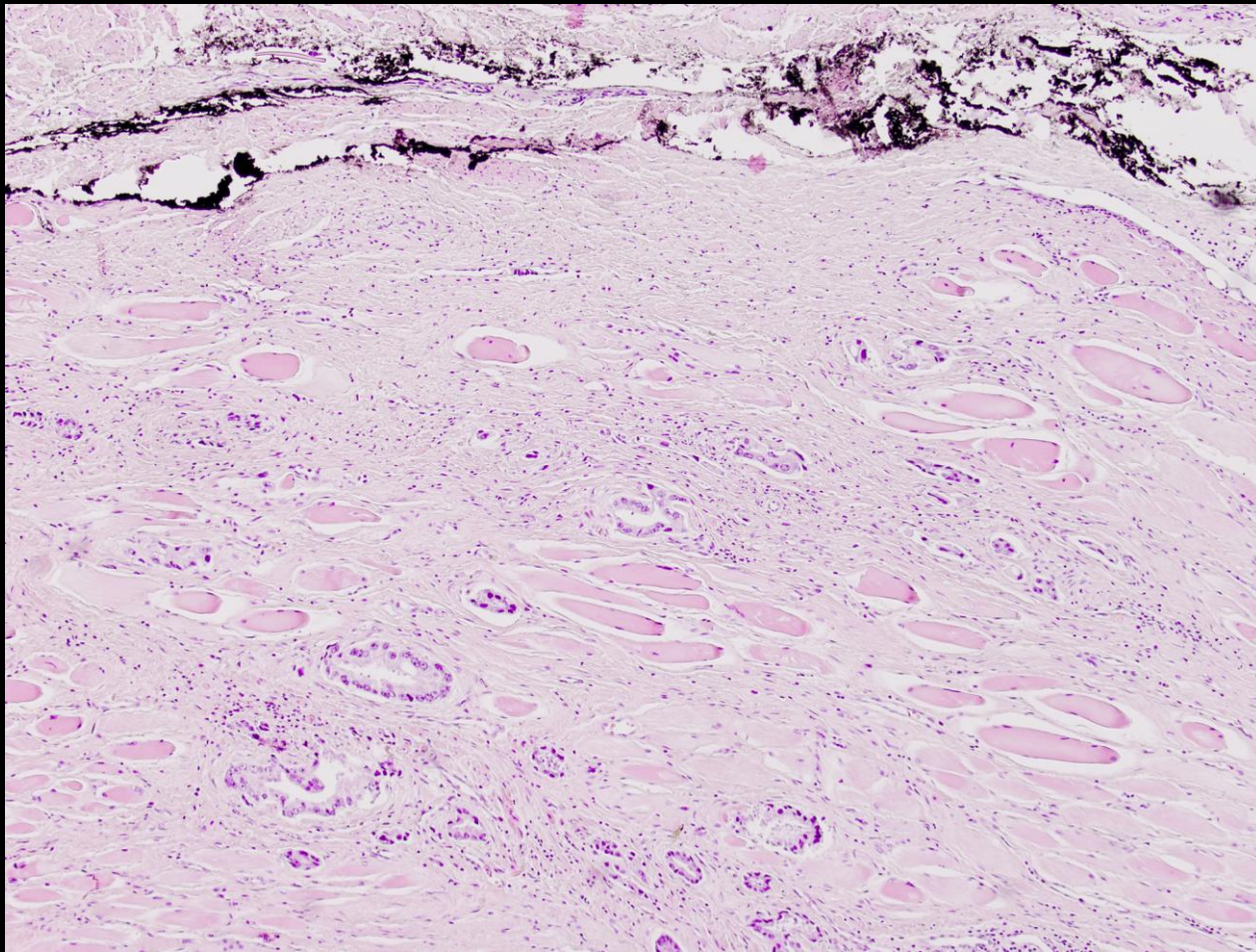
CERRAHİ SINIR + KAPSÜLER İNSİZYON



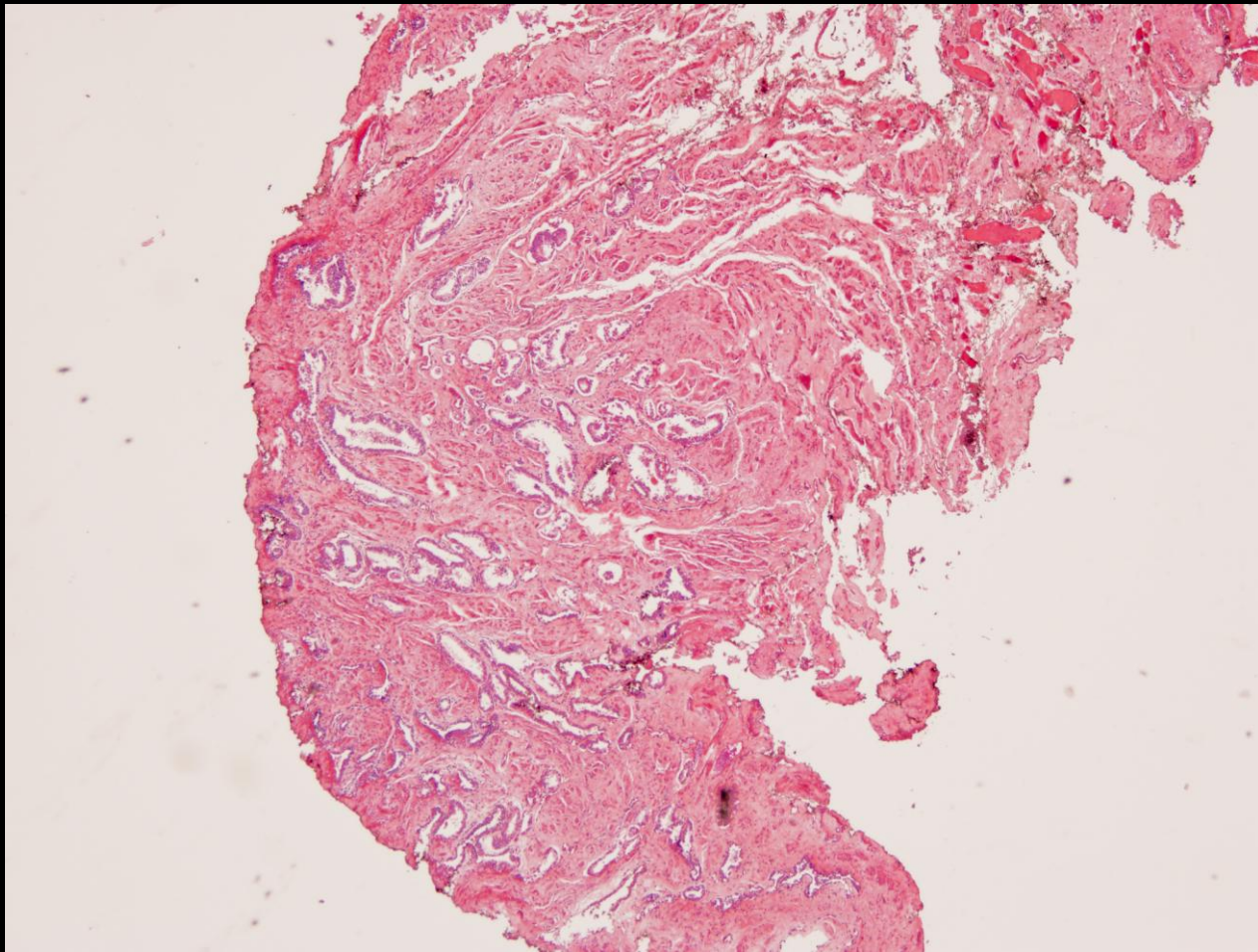
CERRAHİ SINIR + KAPSÜLER İNSİZYON



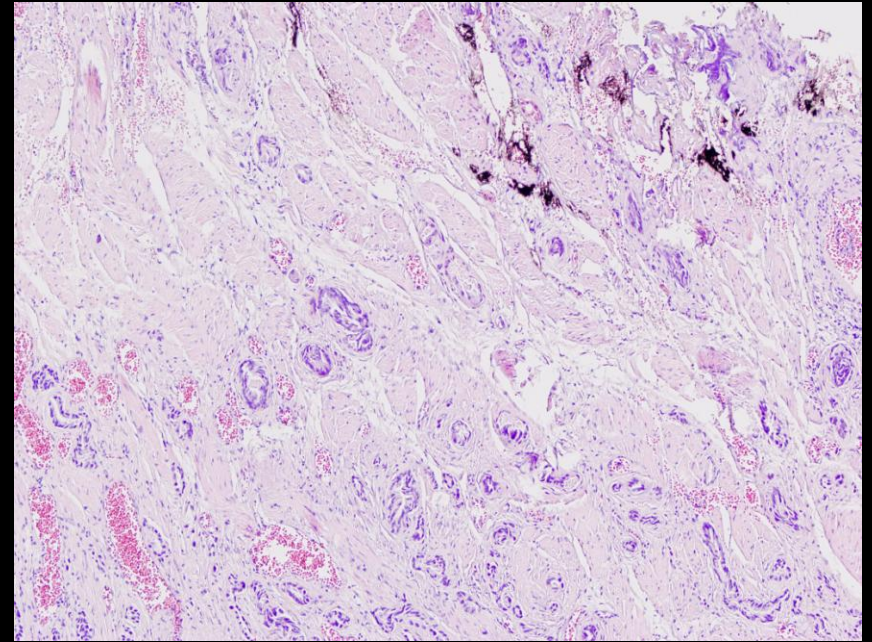
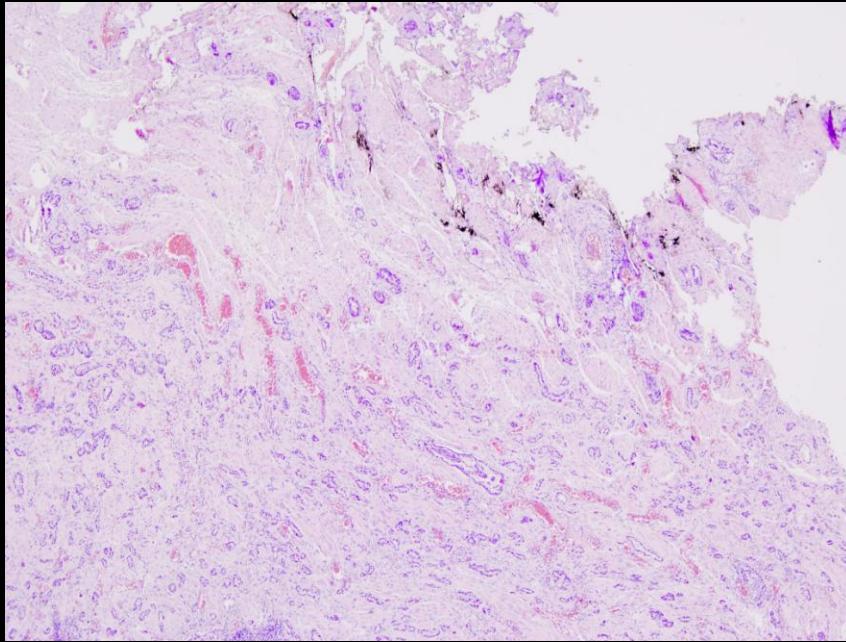
APIKAL CERRAHI SINIR



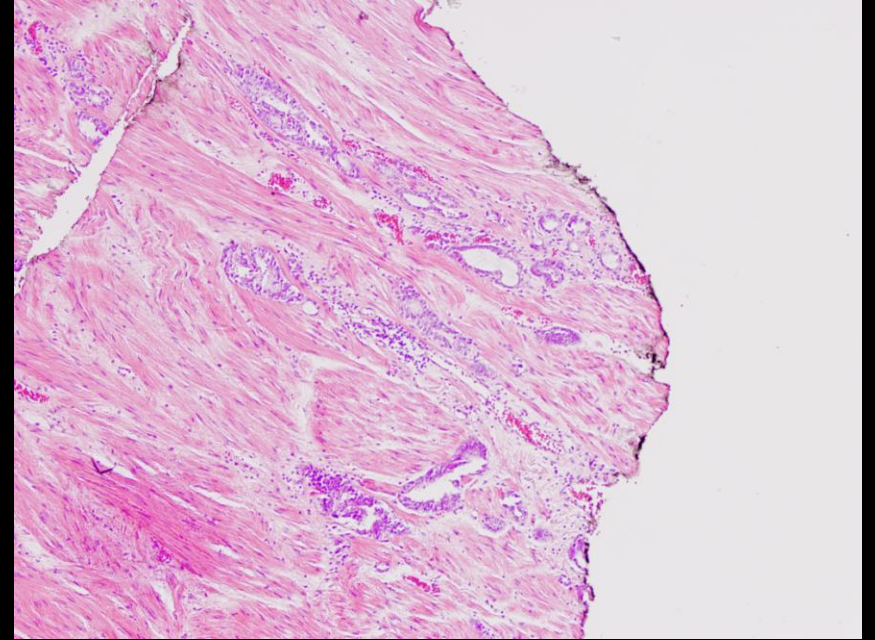
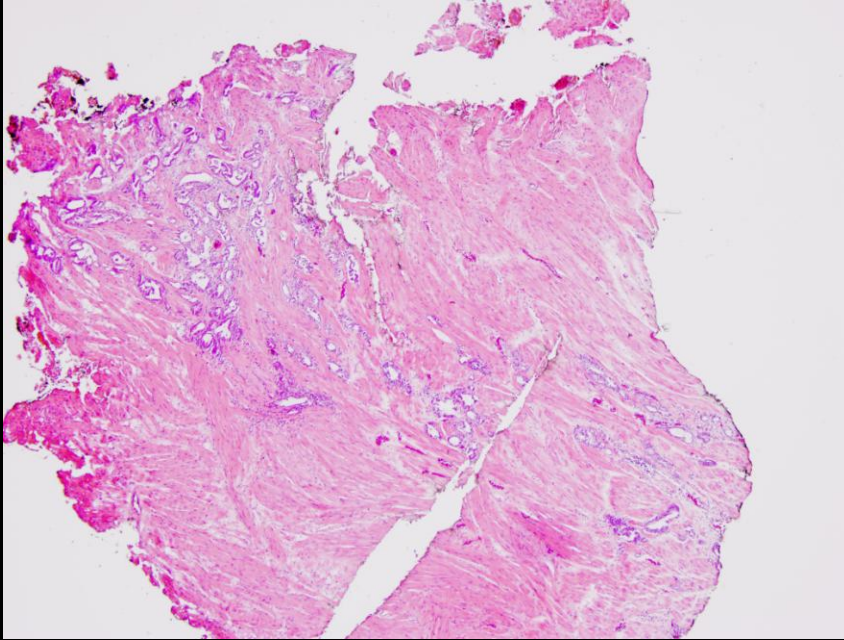
APIKAL CERRAHI SINIR + KI



MESANE BOYNU CERRAHİ SINIRI



MESANE BOYNU CERRAHI SINIRI



CERRAHİ SINIR

- Sağ veya sol
- Posterior
- Posterolateral
- Lateral
- Anterior
- Apikal
- Orta hat
- Mesane boynu

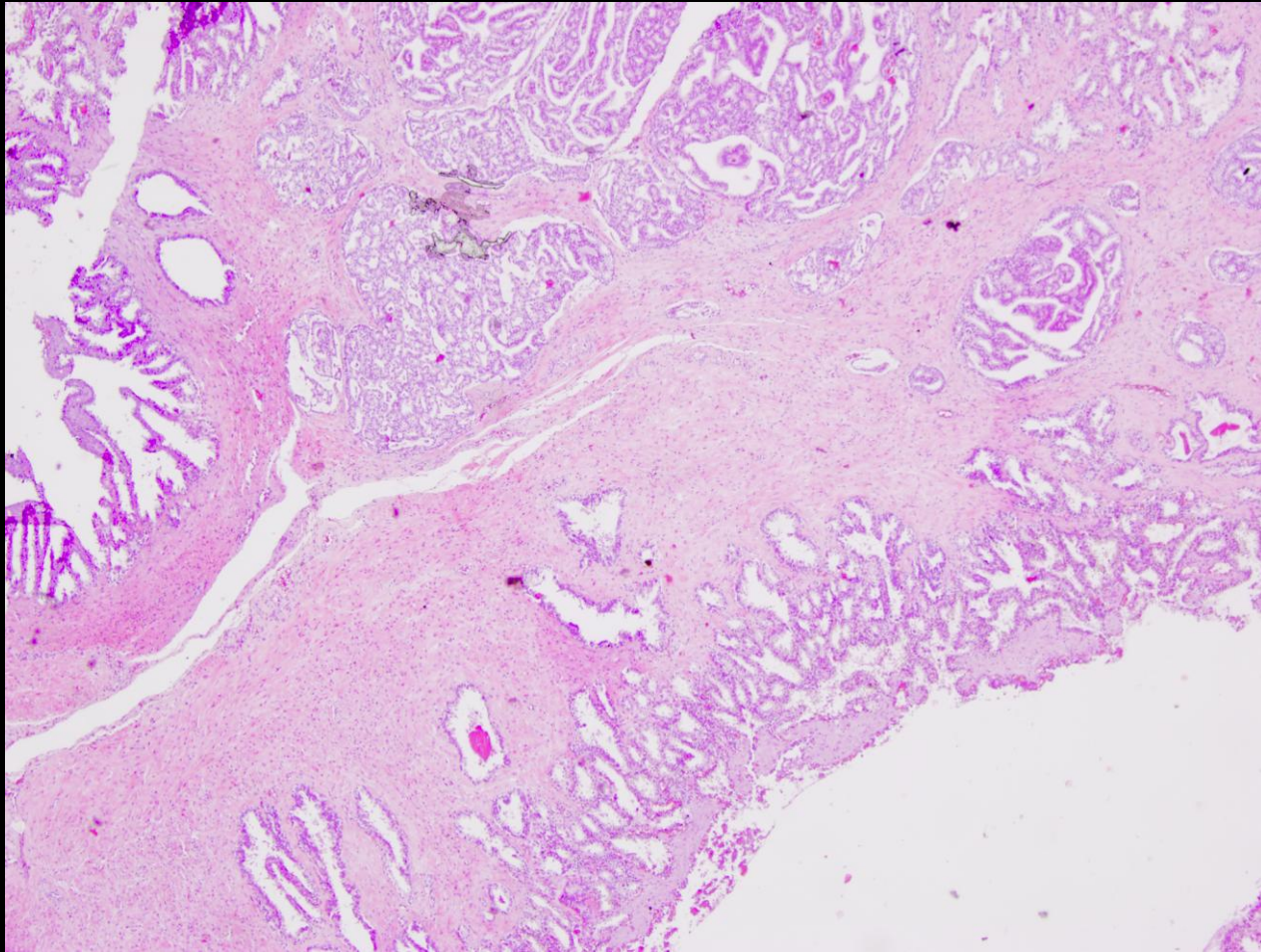
CERRAHİ SINIR

1. Bir kaç bezden ibaret ise fokal, daha fazla ise yaygın
2. 1 büyük büyütme alanından küçükse fokal, büyükse yaygın
3. **Lineer veya radyal uzunluk ölçümü**
4. Oküler mikrometre veya grid ile ölçüm

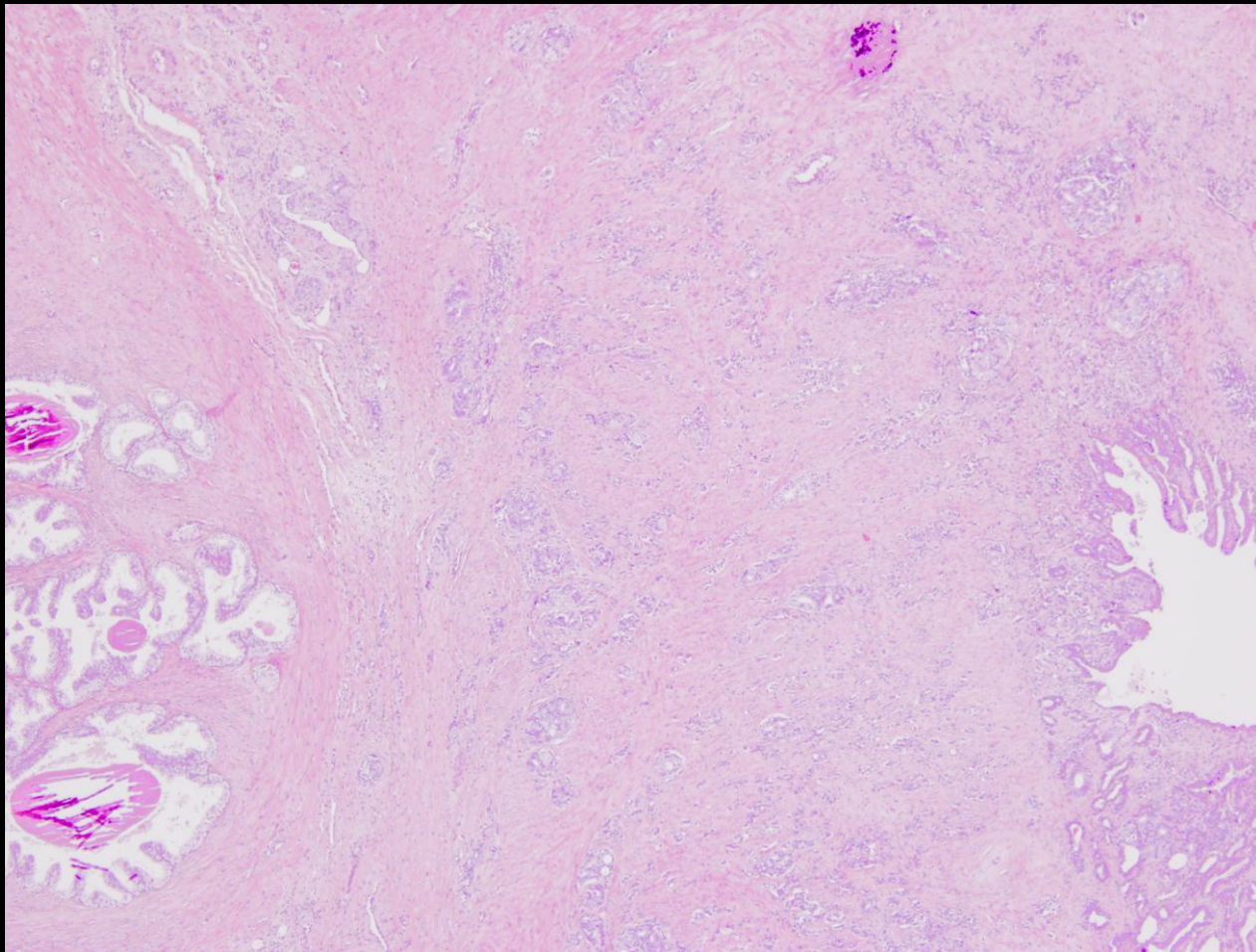
V. SEMİNALİS İNVAZYONU

1. Ejakulatuar duktuslar boyunca yayılarak (tip 1)
2. Prostat tabanından doğrudan invazyon ile veya önce çevre yumuşak dokulara oradan v. seminalise yayılarak (tip 2)
3. Metastaz yolu ile

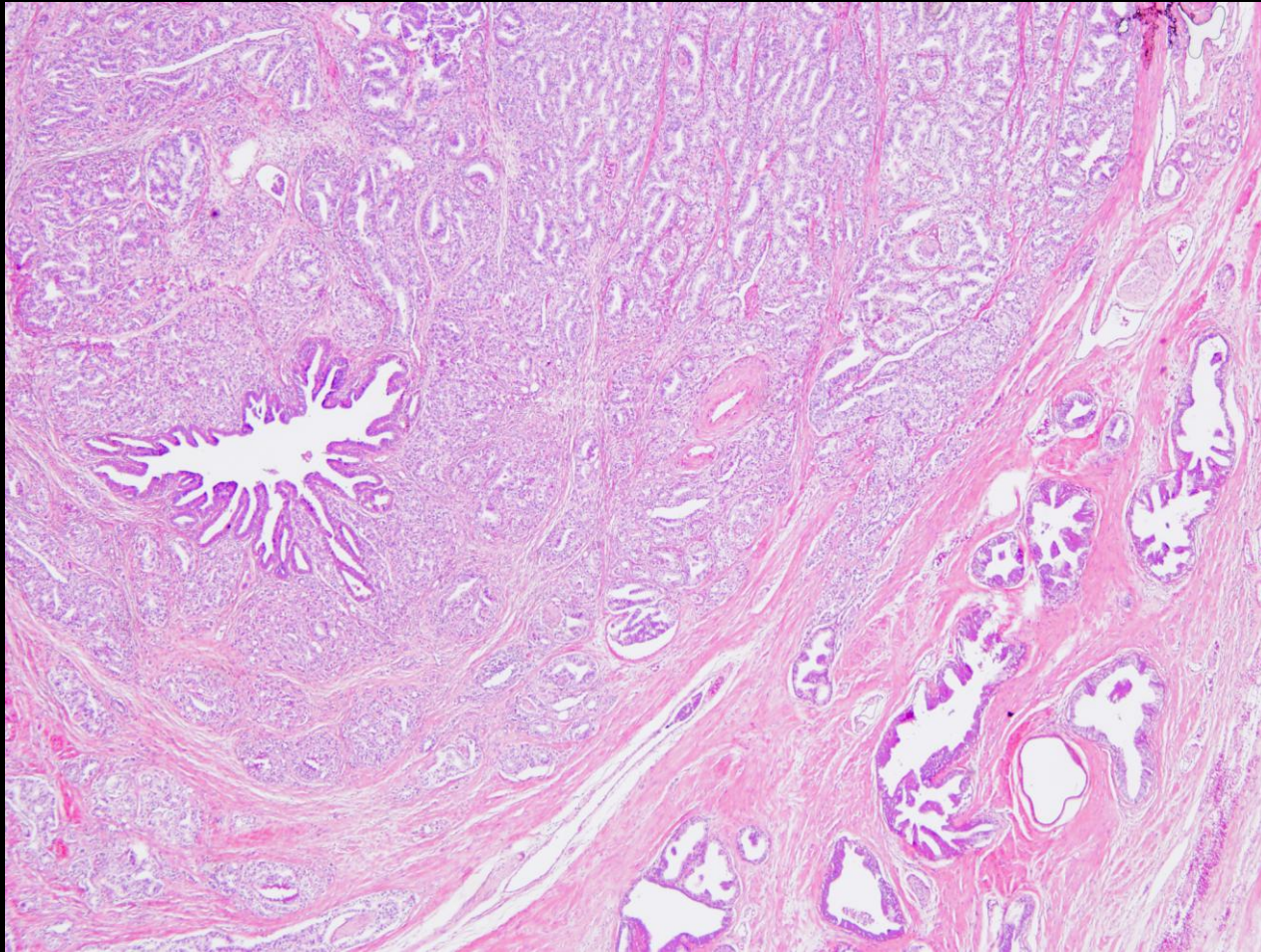
V. SEMINALIS İNVAZYONU



V. SEMINALIS İNVAZYONU Ø

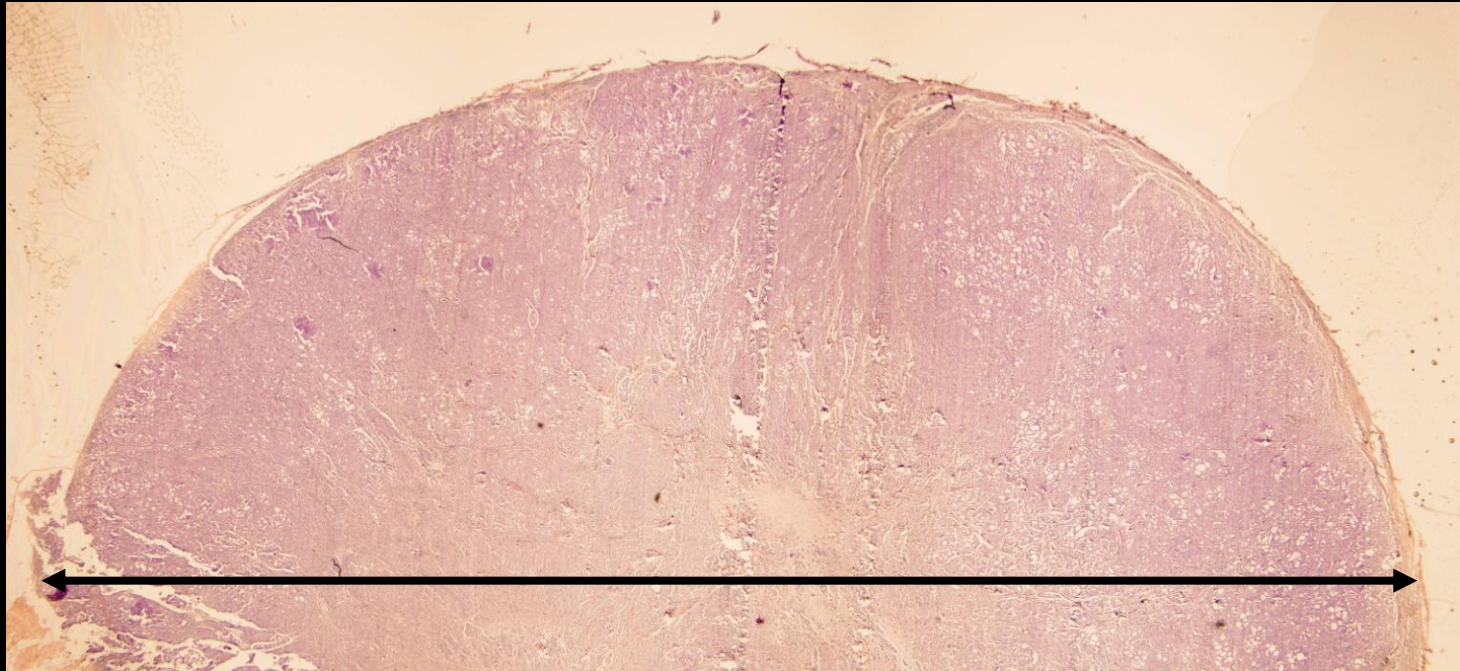


EJAKULATUAR DUKTUS İNVAZYONU



LENF DÜĞÜMÜ METASTAZI

- En büyük çapı
- Kaç adet lenf düğümünde
- Ekstrakapsüler yayılımı



TÜMÖR HACMİ

- Görüntü analizi
- Stereoloji
- En büyük tümör çapı
- Tümörlü blok sayısı
- Tümörlü blok/toplam oranı
- Lam üzerinden tahmin

Mikroskopi

- **Evre**
 - pT2
 - pT3a
- **Dominant/indeks tümör lokalizasyonu**
 - **Anterior**
 - **Periferik zon**
 - **Transizyonel zon**
- **Ekstraprostatik yayılım**
 - Fokal/yaygın
 - Lokalizasyon
- **Cerrahi sınır**
 - Fokal/yaygın
 - Lokalizasyon
- **Lenfovasküler invazyon**
- **Tümör hacmi**
- **Lenf düğümü metastazı**
 - Sayısı
 - Ekstrakapsüler invazyon

